

SUCCESSFUL TREATMENT OF CHRONIC IDIOPATHIC THROMBOCYTOPENIC PURPURA (ITP) DISEASE BY HOMOEOPATHY: A CASE REPORT

Dr. Jyoti Pankaj*¹ and Dr. S. M. Singh²

¹M.D. (Homeo), Director, Pankaj ENT Hospital Private Limited 56-C Singar Nagar, Alambagh, Lucknow-226005.

²Director, Sri Sai Nath Post Graduate Institute of Homoeopathy, 109/4, J.L. Nehru, George Town, Allahabad (UP) 211002.

Received on: 20/11/2020

Revised on: 10/12/2020

Accepted on: 30/12/2020

*Corresponding Author

Dr. Jyoti Pankaj

M.D. (Homeo), Director,
Pankaj ENT Hospital Private
Limited 56-C Singar Nagar,
Alambagh, Lucknow-226005.

ABSTRACT

Idiopathic thrombocytopenic purpura (ITP) is an auto-immune bleeding disorder, mostly females of ages 20-40 of reproductive age & children are affected with this ITP disease, which increases with age & are dependent upon the surgical interventions, immune suppressive medicines, steroids etc., treatments in allopathy for lifelong without complete cure & are at risk for pregnancy, diabetes, heart disease, kidney disease, hepatitis, even for repeated invasive laboratory test procedures. Therefore alternative medicines give a second thought for the treatment for chronic ITP disease, as to avoid complications & health risks. Here author presented a case study of a successful treatment of chronic ITP disease of a 40year-old Muslim female patient by homoeopathy. **Case Profile-** A 40 year-old female patient with heavy menstruation of 8-12 days with pain since 7-8 months, having 38,000 platelet counts, was considered for treatment in the present study. Based on her complete case history, individualization, homoeopathic medicine *Calcarea fluorica* with 3X potency was prescribed to her. **Conclusion-** This case report suggest a positive role for the treatment of chronic ITP disease Patients, without allopathic treatment support, by homoeopathy & can be very, safe, economical, for normal routine life. *Calcarea fluorica* medicine can be prescribed for treatment in chronic ITP patients, as justified in this case report, but critical & severe ITP Patients should involve allopathic emergency management until life stability along with this homoeopathic treatment. Randomized control trial is suggested to ascertain the results obtained in this present case study of successful treatment of chronic ITP disease by Homoeopathy.

KEYWORDS: Auto-immune disorder, *Calcarea fluorica*, Homoeopathy, Idiopathic Thrombocytopenic purpura, Thrombocytopenia.

INTRODUCTION

Case report of a fair, fatty female of 40 year, with heavy menstrual flow of 8-12 days with early menstruation every month, with earlier diagnosed chronic ITP disease with low platelet count as 38,000/cu.mm is considered for ITP disease treatment, as, this incidence increases with age, with a predominance of female only among middle aged adults.^[1] This disorder develops insidiously and persists for several years.^[2] she was taking allopathic treatment since 7-8years before this presented case of homoeopathic treatment. This case was treated with Pseudo-psoric, a kind of mixed miasmatic diseases,^[3] with the concept, homoeopathy treats the patient not the disease,^[3] by complete case history, symptoms approach for individualization & constitutional.^[4,5,6] by considering, the important obstacles to cure.^[3] Haehl says to Hahnemann, PSORA is a disease or disposition to disease, hereditary from generation to generation for

thousands of years, and it is the fostering soil for every possible diseased condition.^[3]

In this case psoric medicine is given first, after making a constitutional drug picture concept with totality, as of *Calcarea* group like fatigue, fear, sleep discomfort, anxiety, chill etc. were present, with intermittent skin & hair itch with eruption in mid follow-ups, & were well treated with totality of symptoms,^[7] by deep psoric medicine *Calcarea carbonica* & *Silicea* etc.

But due to mixed miasm complete cure not achieved, by only psoric medicine. Along with, peculiar symptoms,^[7] of throat of *Calcarea fluorica*, also more of total symptoms with syphilitic manifestation, found in *Calcarea fluorica* including maximum totality of symptoms by later consideration, & as explained that *Calcarea fluorica* should be studied in its symptoms of the mind and larynx in connection with its relative *Calarea carbonica*,^[8] So *Calcarea fluorica* is selected

for remaining miasmatic cure, after evaluation to treat this chronic ITP patient, which made the this patient stable and after that no new abnormal discomfort symptoms arised & gave complete cure as justified under justification, discussion & conclusion of this case report which was not achieved in this chronic ITP patient by allopathy. Well written as, by the incorrect and weakening allopathic treatment, confinement at sedentary occupation and gloomy, close room, weakening vital force, the sad losses of beloved, relatives bending down the soul with grief, or daily vexation and annoyance, which embitter the life, deterioration of the food or an entire want of what is necessary and indispensable then the psora, which has hitherto slumbered awakens and break out as the several severe nameless (Psoric) chronic diseases.^[3]

Epidemiology-The incidence of ITP is 0.2-0.4 new cases per 10,000/year in adults.

Gender- After age 60 years, men predominate again.^[9] The high risk of bleeding in aged patients is remarkable because old ITP patients are rarely examined separately even in the largest series.^[10]

Seasonal variability-It is assumed that infections that can trigger ITP are more frequent in winter. patient was treated for recurrent throat symptoms in mid of follow-ups. **Ethnic variability**-older studies find a lower incidence in African Americans while in the Asia-Pacific region ITP seems to be as frequent as in Europe. **Clinical Presentation**-The central clinical symptom- exhaustion and fatigue, including depressive disorders of ITP is the increased bleeding tendency, Petechiae and mucosal hemorrhages are typical. Many ITP patients also complain of exhaustion and fatigue, including depressive disorders,^[9] as seen in this presented case report of ITP disease.

Material and Methods-A Female 40-year patient with chronic ITP disease with following details-

Present complain-Heavy prolonged painful menstrual bleeding of 8-12 days with early menses every month with aggravation on mental & physical exertions since 7-8 months with fatigue, unrefreshing sleep and backache intermittently.

Present history-Religion-Muslim, low-middle-socio-economic status, house-wife with joint family living conditions, dependent. Work stress of whole family, Introvert, shy, nature, weeping tendency. Heavy painful, prolonged menstrual bleeding worse on physical & mental exertion, anxiety. First came with 38,000/cu.mm. Platelet counts and with earlier diagnosed ITP.

Family History- Her father a low-middle class businessman with normal health, mother is suffering from diabetes and Patient's mother had benign tumor in Uterus.(As told by the patient) Tumor was operated

because she also had profuse bleeding. Patient's mother is diabetic now. Patients has 3 younger sisters and 4 younger brothers & has two sons.

Detailed Personal History- Symptoms of patients are following-

1. Mental general- (Arising from mixed miasm), **Mind**- Anxiety due to fear, noise, future, bad news and thinking of the symptoms and due to emotional excitement. Fear worse in evening, weeping tendency, tearful.
2. Physical general-**Chill**- chilliness worse after cold bath and exposure to draft of cold weather. **Sleep**-disturbed, unrefreshing, **Headache**-worse after mental and Physical exertion better by rest, quiet, sleep, eating sometime.
3. Particular General-1-**Head** – eruptions on scalp and dryness, itching worse cold weather, hair fall, 2-**Throat symptom**- Pain worse by cold drink and cold weather, Clearing, scraping and suffocative feeling worse in cold air and in cold weather. All throat symptoms better by warm drinks. (intermittent symptoms), 3-**External throat**: Cervical lymph nodes on neck on both sides of neck(intermittent symptom),4-All symptoms of throat better by warm drink and warmth,5-**Desire and Aversion**-Craves meat, 6-**Larynx and Trachea**- Dryness, pain, irritation and tickling sensation from cold air. Worse on waking in morning especially in cold weather,7-**Stomach**: Flatulence, worse after heavy meal, 8- **Back**: Pain and chill in damp weather, 9-Abnormal heavy menstrual bleeding-as bright and sometimes light pale in color with or with pain, flow more on mental and physical exertion.10-Skin-itch with very small eruptions on whole body(intermittent symptoms during follow up).

Modalities- worse during rest, change of weather. Better heat, & warm application,^[6] The symptoms are worse in damp weather,& better by heat, Throat better by warm drinks.^[8]

Past History of patient-Since after her two child delivery in 2000 and 2002, by Caesar operations., she is having backache and pain during menses, prolonged menstrual bleeding, later developed adenomyotic tissue changes in uterus with some myoma as figure -7 which was operated, had biopsy as below, with intermittent throat symptoms.Following other Reports are mentioned below of chronic ITP patient of this presented homoeopathic treatment case report-
A-Figure-1Haemoglobin-11.8g,
B-Figure-1-Liver function test, Creatinine serum, Blood sugar, Uric acid serum -Normal Range
C- Figure1,2,3,4-variable platelet counts as 44,000, 38,000, 41,000,21,000/cu.mm. respectively,
D-Figure-5-Bone Marrow Aspiration test -Bone marrow smears show adequate megakaryopoiesis.

E-Figure-6-Biopsy-Section shows bits of endometrial tissue comprising of proliferative to early secretory glands in a cellular to congested oedematous mucosa, there is no evidence of granulomatous inflammation or malignancy in tissue provided,

F-Figure-8-Ultrasound TVS-lower abdomen shows bulky uterus with adenomyotic change, & with Kidneys, Urinary bladder, Ovaries/adenexa-Normal
 G-Figure-9&10, as HIV, Hepatitis B, Hepatitis C, & Dengue respectively--Negative
 H- Figure-11-ECG-Normal,
 I-Figure-12Suggestive of Bronchitis.

Past Treatment History-Figure-13-Allopathic treatment of steroids before this homoeopathic treatment.




Figure No. 1



Figure No. 2

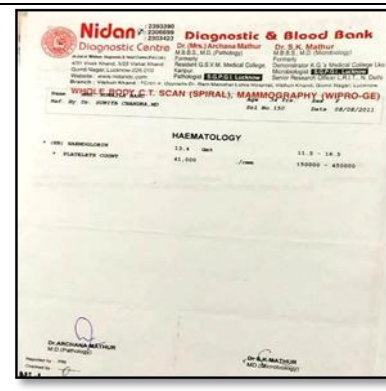


Figure No. 3

Fi




Figure no.4




Figure no.5

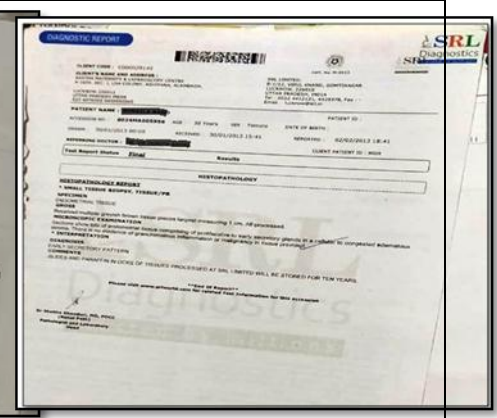

Figure no.6




Figure no. 7




Figure No. 8




Figure No. 9




Figure No. 10




Figure No. 11




Figure No. 12




Figure No. 13

Follow-up Detail

After considering complete case history & all earlier follow-up observation of treatment & reports of patient, the general examination of patient is done as her B.P.-110/75mmHg, Pulse-62/minute, weight-63kg, Ht-5feet2', general body appearance-fair pale face, introvert in nature. In her first visit on 28 November, 2015, she explained very few symptoms like heavy bleeding and fatigue so due to less symptoms, therapeutic prescription(6) concept was taken 1-,with medicine *Vinca minor Q-8-10* drop 3 times a day due to heavy bleeding, slight hair itch, with tumor history, for 5 days after 5 day in prescription, she reported that very slight **amelioration** in bleeding amount, then 2nd time prescription was 2-*vinca minor Q* as before along with *Calcarea carbonica 6c*, 1 drop as single dose, 6 hourly for 20 days. 3-Next visit she gave good response & have some new symptoms came after 2nd prescription, as headache, numbness in legs, taking these symptoms 4-*Plumbum metallicum 200 C*, single dose, once in 20 day & *Calcarea carbonica 6C*, one drop as single dose, 6 hourly was prescribed in 3rd visit for 20-days, In her 3rd visit she was having smile and more satisfaction as her headache completely gone numbness of legs minimized very much with little more relaxation in her menstrual pains. 5- Further visits at interval of 1-1 month with same prescription by totality of symptoms upto 15, March 2016 gave good results to improve her health with no headache and numbness with less menstrual bleeding & platelet counts increased 82,000/cu.mm. 6-Again in this visit Prescription is repeated as in next successive visits, in many follow ups for 1-1 month, she was better in

initial 2-3 successive follow-ups, but due to her economic & family condition & work load she could not continue the treatment for 3-4 months, then she came in 28 November, 2015 with again low platelet & bleeding complain, though not all pain but itch rashes all over body & sculp, also at urinary meatus sleep disturbed as told by her, This time *Silicea 200C*, 3dose, *Calcarea carbonica 6C*, 1 drop dose as single dose 6 hourly, according to totality, again she with cure of earlier symptoms improved but not to stability, whenever she lacked nutrition and care, her improvement decreases, then in her successive visit she came with some cervical lymph nodes on neck on both sides, which got cured very soon in mid follow-up with alternate constipation & diarrhea symptoms, & also having peculiar scraping, tickling painful sensation in throat along with less bleeding than before so again totality is made of all the symptoms to find correct remedy, *calcarea fluorica 3X*. This time *Calarea fluorica* is rated as best selected medicine according to homoeopathic concepts of miasm. Now author prescribed the *Calcarea fluorica 3X*, 6 tab, 6 hourly daily with 1-1 month follow-up, with diet care as explained in discussion of this case, to avoid any infections, with more fluid healthy meals intake. After prescribing *Calcarea fluorica 3X*, no new abnormal symptoms arised, she improved wonderfully by this prescription with all ease, except backache of low intensity with raised platelet count, next similar prescription is made in her following successive visits, everytime she came with more cheerful mood and smile with improved health by this prescription.

Time-line of case Report-Table No. 1

SN.	Date	Platelet counts/cu.mm	Main symptoms During follow-ups	Homoeopathic Medicine Prescribed
1.	28-11-2015	38,000	Heavy menstrual painful, prolonged bleeding of 8-12 days, Fatigue, Backache, Anxiety, Interovert	<i>Vinca Minor Q5-10drop 3times. Calcarea Carbonica 6C- 1drop. 6 hourly 20days</i>
2.	15-03-2016	82,000	Heavy Menstrual painful bleeding, Headache, Numbness in legs, anxiety, craving for meat, Backache	<i>Pulsam metallicum 200C- 3 dose 15-15 minutes interval once only in 1 month, Calcarea Carbonica 6C, 1drop as single dose 6 hourly for 1 month</i>
3.	22-11-2016	67,000	Menstrual flow of 12 days with less pain, no headache, numbness, new itch with vesicles-whole body & scalp, urine meatus itch, sleep disturbed, Less anxiety	<i>Silicea 200C 3dose at 15-15 minutes interval once only in a month, Calcarea Carbonica. 6C- 1drop, single dose -hourly for 1 month</i>
4.	27-11-2017	74,000	Menstrual flow 12 days as before, itch of body & urine cured, alternate constipation-diarrhea Backache	<i>Calcarea Carbonica 6C, 1drop -hourly -1month</i>
5.	13-04-2018	45,000	Menstrual flow of 12 days with less pain, cervical lymph nodes on both sides of neck, throat pain Dry cough, Backache, Fatigue sleep disturbed.	<i>Calcarea fluorica. 3c-6tab-6 hourly for 1 month</i>
6.	08-12-2018	86,000	Menstrual flow without pain of 8-9 days, throat pain, cough, Decreased, cheerful mood	<i>Calcarea fluorica 3c-6tab-6 hourly -1month</i>
7.	13-04-2019	65,000	More fatigue due to long gap of medicine due to some family stress and work load & lacking nutritional Menstrual flow of 10 days with Exhaustion	<i>Calcarea fluorica. 3c-6tab-6 hourly -3month</i>
8.	16-12-2019	1,54,000	Menstrual flow of 7-8 days without any new abnormal symptoms, Cheerful Mood, sleep better, all discomfort symptoms gone	<i>Calcarea fluorica. 3c-6tab-6 hourly for 3month</i>
9.	12-6-2020	1,93,000	Normal menstrual Flow of 3-5or 6 days without pain & discomfort, cheerful mood, Better routine work capacity. No new abnormal symptoms.	<i>Calcarea fluorica. 3c-6tab-6hourly for 3month</i>

Whenever she fails to overcome her stress of mental or physical, or nutritional requirement, she lacked improvement progression in mid follow-ups. Many times she never came for follow-ups due to her family stress on

time. Diet and stress management is the most important factor for the of chronic ITP disease patients as their stress bearing capacity is lower than normal healthy person, due to low immunity.

Table 2: Repertorization table according to Kent Repertory. [11]

Name of Medicines		Calcarea Carbonica	Calcarea fluorica	Pulsatilla	Staphisagria	Silicea	Conium Mac.
Totality		27	27	9	8	8	4
Symptoms covered		11	14	4	5	8	2
Symptoms-							
1	Anxiety from fear of future and bad news	3	3	2	2	-	1
2	Mind- Anxiety from fright and thinking of symptoms	1	1	-	1	2	-
3	Dullness during menses and mental & physical exertion	1	1	-	-	-	-
4	Fear worse evening	3	3	-	-	-	-
5	Weeping tendency and tearful	3	3	3	-	-	-
6	Sleep- Dreams frightful	3	2	3	1	3	3
7	Sleep disturbed by dreams and unrefreshing	-	-	1	1	1	-
8	Chill- Chilliness by cold bath and draft of cold weather	3	3	-	-	1	-
9	Head- small dry, crusty eruption	2	2	-	2	2	-
10	Larynx & Trachea- dryness and itching in trachea, worse in cold air and cold weather	2	2	-	-	1	-
11	Recurrent irritation in Larynx mostly in cold weather	2	2	-	-	-	-
12	Tickling and suffocative feeling of throat, worse in cold weather	3	3	-	-	2	-
13	External throat- cervical gland on sides	1	1	-	-	1	-
14	Profuse menses bleeding- (enlarged bulky uterus with benign myomas history and with low platelet count for long duration), Bleeding with bright and sometimes light red or pale colour with or without pain, flow more on exertion	-	1	-	-	-	-

Justification: Patient of this case report, having heavy prolonged menstrual bleeding symptom along with earlier diagnosed Chronic ITP disease is successfully treated by homoeopathy, with Pseudo-psoric-miasm as chronic mixed type. Miasm denotes the dynamic disease producing power which stains and pollutes the human organism with unhealthy tendencies and thus becomes the producer of different types of diseases. [7] They are ineradicable by the vital force alone without proper medicinal treatment. Here the mode of development of psora, is under as secondary manifestation of external ailments. Syphilis complicated with psora-such complication-(According to Dr. Hahnemann) may be developed in two ways-(a) when the man the time of the syphilitic infection was already suffering from a chronic

disease so that syphilis was complicated with the psora, even while the chance yet existed. [3]

Totality of symptoms of *Calcarea carbonica* is 27 same as in *Calcarea fluorica*, but the number of symptoms are more found as 14, of *Calcarea fluorica* medicine. So, *Calcarea fluorica* is the best, correct indicated prescribing remedy for the treatment of chronic ITP disease. Symptoms, including its peculiar throat symptoms as particularly found only in *Calcarea fluorica* as eliminating symptom long with modalities & other symptoms, as physical general, mental general symptoms with strong dominance of evaluating symptoms of mental general-anxiety, fear and physical general-chill taking mixed miasm of pseudo-psora, &

totality, with approach of homoeopathic concepts, are taken ,as to improve the immunity & also to treat the chronic ITP disease.

This patient was also having the symptoms of skin itch eruptions on scalp as well on whole body in between the treatment& cured with psoric medicine *Silicea* 200C 3dose in mid follow-up, though her platelet counts were increased to normal but were not stable to normal values, which confirms that psora miasm was cured, as, in order to cure secondary psora,anti-psoric medicines given and by anti-psoric medicine if the eruption be brought back, then the psora is cured.^[3] In totality of symptoms and repertoisation *Calcarea carbonica* & *Calcarea fluorica* have same score-27,but *Calcarea fluorica* have more number of symptoms along with syphilitic background,& also peculiar & evaluating throat symptoms, So *Calcarea fluorica* is best selected medicine cure, though some intercurrent psoric medicines like *Calcarea carbonica*, *Silicea*, *Plumbummetallicum* are used to treat psoric background miasm and(syphilitic miasm remained, which causes more new abnormal symptoms arise,due to syphilitic miasm & platelet count unstable below normal value). So, *Calcarea fluorica* is selected for the most of symptoms to cure after psoric-miasm treatment.

The potency 3x was selected as when gross pathological changes have taken place, it is safer and more effective to use a low potency of the indicated remedy.^[3] Frequent repetition of low potencies in chronic conditions seems to be generally acceptable.^[12] Repeated doses of a low potency of the remedy are given till the patient is cured. Some other homoeopathic medicines can be used in chronic ITP disease treatment considering this case report, if totality, individualization, miasmatic approach with symptoms matches, as with correct indicative remedy, like *Calcarea carbonica* as explained in introduction of this case report, or *Fluoric acid* due to miasm (comparing with *Calcarea fluorica* in its sleep symptoms with *Fluoric acid*)^[8] & (syphilitic-background)

with potency according to homoeopathic concepts.^[4] In this case report *Calcarea fluorica* is the selected remedy for treatment of chronic ITP disease according to homoeopathy. According to miasm found in this ITP chronic disease, a large % of patients of chronic ITP disease can be cured by this homoeopathic medicine *Calcarea fluorica*, because all these symptoms may be found, in chronic ITP disease patients, as tissue degenerations and syphilitic manifestations, of different grades & organs.

In acute crisis with chronic trouble medium or low potency because the high potency would stir up more than the vital force could cope with in the pace of advanced chronic pathology.^[3]

The lower preparation should be used in chronic disease with tendency to disorganization of tissues.^[3]

Calcarea fluorica is selected which bears the greatest similarity to the totality of symptoms observed in a given case of natural disease. This medicine will and must be the most suitable, most certain homoeopathic remedy.^[12] Also according to Hering'S Law OF CURE, As-1.From above Downward, 2.From Within Outward, 3.From an important organ to less important organ, 4.In the reverse order of their appearance, the first to appear being last to disappear,^[3] As here the symptoms of throat discomfort changes are last to disappear which were present recurrently since long before, even from her young age of 20s, and then the platelet count became first to be in normal range and then uterine bleeding, In this case report follow-up ,she got platelet count rise from 38,000 to 67,000, 87,000, 1,20,000, 1,54,000, & last report attached as 1,93,000/cu.mm. As Figure 2, figure 14, 15, 18, 16, 17. Some earlier follow-up have unstably but later continuous rise of platelet to normal range. The result of homoeopathic treatment of this presented case report of chronic ITP patient, is, as follows-

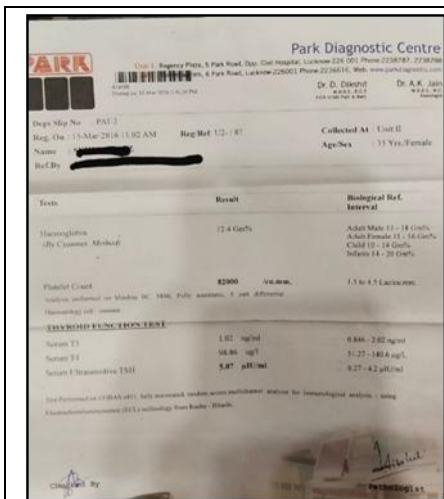

Figure No. 14



Figure No. 15



Figure No. 16




Figure no. 17




Figure no. 18

A- Shown in Figure 17-The platelet counts increased to 1,93,000/cu.mm. to normal, B-Shown in Figure 18-Improved complete blood cells count report with improved haemoglobin to 13.1g, C-With normal menstrual flow of 3-5 days without pain every month as normal routine.4-she is active and happy now for her normal routine life. In this case report, patient of chronic ITP disease, is successfully treated, without support of allopathy, by Homoeopathy by medicine *Calcarea fluorica* with 3X potency in approximately 3 years of time.

DISCUSSION

Worldwide over 200 million people use homoeopathy on a regular basis homeopathy is included in the national health system of a number of countries e.g. Brazil, Chile, India, Mexico, Pakistan, Switzerland. India leads in terms of people using homoeopathy with 100 million people depending solely on homoeopathy for their medical cure.^[13] In India about 13% population consume exclusively homoeopathy formulations for their health issue,^[14] platelet count below, lower limit of normal ie.150,000/cu.mm..^[2] (ITP) Immune thrombocytopenia is an auto-immune bleeding disorder.^[15] Additional symptoms-ITP patients have an increased risk of infections from immuno-suppressive therapies or splenectomy. It has recently been described that ITP per se also increases the risk of infection.^[9-4]

Phases of the Diseases- 3 phases; newly diagnosed verses persistent verses chronic ITP.1-Newly diagnosed-up-to 3months in child &young adult, 2-Persistent Between 3 and 12 months after diagnosis, 3-More than 12 months after diagnosis.^[9]

Diagnosis-ITP is a diagnosis by exclusions, there is no laboratory test or any other method that proves ITP. Diagnosis and differential diagnosis usually occurs in several steps.^[9] Thrombocytopenia, one of the diagnostic criteria for dengue, is being proposed as an important predictive marker for complications, as studies have shown that lower platelet count correlates with higher

complication rate.^[16] Almost two-thirds of all ITP patients over 60 years have **comorbidities** that affect the course and treatment of ITP. The most common comorbidities are hypertension, diabetes, cardio-vascular disease, neuropsychiatric disease, pneumonia, anemia and cataracts. ITP patients are 3 times likely than non-ITP to develop malignancies and lymphomas.^[9]

Homoeopathy denotes individualization to the management of sick as a whole body taking past & present symptoms & if accurately implemented can elicit a intense healing response. So similar way chronic ITP patients can be treated with Homoeopathy, as justified in this case report by ***Calcarea fluorica* homoeopathic medicine to save people.**

Food plays important role in maintaining good health and recovery from illness. Therefore, assessing a patient's nutritional status and identifying her or his nutritional needs are primary activities in the development of health plan.^[17] well-nourished people are more likely to be mentally and physically alert and to have a positive outlook on life. They are also more able to resist infections, diseases as compared with undernourished people.^[17] The Biochemical therapeutics aids nature in her efforts to cure by supplying the natural remedies lacking in certain parts that is, the inorganic cell-salts, and in this way corrects abnormal status of physiological chemistry. *Calcarea fluorica* a tissue remedy is well explained. Also as inorganic constituents of cells and the Theory of Schussler's Bio-chemic method.^[8] If the other patients of ITP with the same totality of symptoms with miasm of pseudo- psora. The selection of potency,^[3] and repetition should be decided according to homoeopathic concepts.

Homoeopathy is well accepted due to its safe, effective, smooth, economical, holistic concept of treatment for many ailments & is more needed for chronic ITP disease patients compared to allopathy,^[7] which is quite expensive as well as have risk of either of, invasive surgical interventions or immunosuppressive medicines,

steroids which lowers immunity,^[3] & sometimes lifelong treatment venture, having stress & fear, even for regular repeated invasive laboratory investigations required in long follow ups without complete health,^[7] cure to lead normal life. Of all pregnancies, 6-12% develop thrombocytopenia.^[9] This case report could be so helpful to treat million ITP disease patients, which would be a new ray of hope for life, especially, the treatment of ITP during pregnancy is more difficult because one has to consider side effects from medication on both the mother and the fetus. Fortunately, the platelet level are usually not.^[9] relevant steroid side effects occur (hypertension, diabetes metabolism, osteoporosis, strong weight increase, psychosis, etc.) Splenectomy is indicated for severe, otherwise uncontrollable thrombocytopenia and bleeding.^[9] in allopathy.

Prognosis and Risk indications. With longer duration of the ITP, the normalization of the platelet count becomes less important as the primary therapeutic goal while quality of life and the avoidance of side effects from treatment gain more relevance,^[9] Quality of life-close to cancer, in some cases even worse.^[9]

Limitations of homoeopathy,^[3] are that, critical & severe conditions in chronic ITP disease patient should involve allopathy for management of critical emergency life care measures for stability, along with homeopathy for holistic speedy cure, which on stabilization can switch to, only homoeopathic treatment, as the highest ideal of cure is rapid, gentle and permanent restoration of the health, or removal and annihilation of the disease in its whole extent in the shortest most reliable, and most harmless way, on easily comprehensible principles.^[18]

Author advised to take calcium supplement as to full-fill her nutritional need for some-time because of her longtime backache, which helped much to get early cure. In this ITP case, which eased her backache pains completely. Low saturated fat, low carbohydrate and least sugar intake along with proper citrus fruits as diet measures.

She is still under treatment, to improve the immunity for more stability, as to avoid infections, especially recent pandemic **covid-19** corona virus like deadly infections etc.

The other patients of chronic ITP with totality of symptoms,^[7] constitution, complete case history considerations could be cured by this homoeopathic remedy *Calcarea fluorica*. Time taken by others with the regular accurate time follow-up & correct diet & regimen measures can be minimized, as she was not regular & her diet & living status was compromised and so stress-free living conditions & care will have good prognosis and chronic ITP patients could be cured to healthy routine life. Despite the significant oppression from the orthodox medical profession, homoeopathy survived.^[19] This is a very effective remedy in Disease of connective tissues

along with dominance of respiratory affections and fear for future and Dreams with sense of danger as explained in this text book. *Calcarea fluorica* is also a constituent of elastic fibers and of epidermis. Elastic fibers are found in the skin, in the connective tissue and in the vascular walls,^[8] used after operations, where the tendency to adhesion is reduced.^[6]

CONCLUSION

It is concluded that positive response and restoration of health in a gentle manner within specific time by homoeopathic treatment, without allopathic treatment support, as observed in the present case report, signifies that Chronic ITP disease can be well treated by homoeopathic concepts by *Calcarea fluorica* medicine. As per homoeopathic literature, *Calcarea fluorica* has profound good action in treating connective tissue cells diseases, and this case report justified this consideration by homoeopathy. Such randomized control trials are suggested with *Calcarea fluorica* medicine for the treatment of Chronic ITP diseases by homoeopathy.

Consent

Written consent has been taken from the patient.

Conflict of Interest

No conflict of interest.

REFERENCES

1. Patrick F Fogarty 1, Jodi B Segal, Affiliations expand The epidemiology of immune thrombocytopenic purpura, *Curr Opin Hematol*, 2007 Sep; 14(5): 515-9. doi: 10.1097/MOH.0b013e3282ab98c7, PMID: 17934361.
2. Harsh Mohan Textbook of Pathology-7th ed, 2015; 311-310.
3. Dr. Asok kumar Das, A Treatise ON Organon OF Medicine (pt 3) Reprint ed. A34, A119-23, A75-76, B8, B18, B73, B19, A60, A57, A58, A71, A52-62, A131-32, 1994.
4. James Tayler Kent, Lectures on Homoeopathic Materia Medica Reprint ed, 1996; 311-31.
5. DR. M.L. Tyler, Homoeopathic Drug Pictures, Reprint ed, 1995; 153-64.
6. Willam Boericke Pocket Manual of Homoeopathic Matura Medica & Repertory 9th Reprint ed, 1997; 144-48, 149-50.
7. Dr. Asok Kumar Das, A Treatise on Organon of Medicine, Reprint ed March (pt-I), p.81, 78, 163, 164, 105-107, 57, 81, 2018.
8. Boericke & Dewey, M.D, The Twelve tissue remedies of Schussler,^{3rd} ed- p.43, 43, 15, 37.
9. Matzdorff A. a Meyer O. b Ostermann H. c Kiefel V. d · Eberl W. e Kühne T. f Pabinger I. g Rummel M. h, Immune Thrombocytopenia - Current Diagnostics and Therapy: Recommendations of a Joint Working Group of DGHO, ÖGHO, SGH, GPOH, and DGTI.
10. *Oncol Res Treat*; 41(suppl 5):1-30, p.2, 4, 4, 5, 6, 23- {144, 145}, 21, 22, 23, 5, 24- {149}, 2018.

11. Sergio Cortelazzo, Guido Finazzi, Maurizio Buelli, Anna Molteni, Piera Viero, and Tiziano Barbui, High Risk of Severe Bleeding in Aged Patients With Chronic Idiopathic.
12. Thrombocytopenic Purpura, *www.bloodjournal.org*, 1991; 77(1): 32.
13. J.T. KENT, Repertory of the Homoeopathic Materia Medica and A Word Index, Reprint ed, 1991.
14. DR. A. k. Das A Treatise on Organon of Medicine, Reprint ed, 1992; (pt 2): 75,28.
15. *www.hri-research.org/resources/*. [internet].
16. Akshaya Kumar Hati, Sasmita Rath, Chintamani Nayak, Induprava Raj, Amulya Ratna Sahoo, Biswaranjan Paital, Successful treatment of ureteric calculi with constitutional homoeopathic medicine *Lycopodium clavatum*: A Case report, Treatment of ureteric calculi by *Lycopodium clavatum*, *Journal of Drug Delivery and Therapeutics*, VOL 8 NO 6 (2018):8(6):2. VOLUME 8, ISSUE 6 NOV-DEC, 2018.
17. NORD, <https://rarediseases.org/organizations/itp-foundation>. [Internet].
18. Debadatta Nayak, Vishal Chadha, Shruti Jain, Priyanka Nim, Jyoti Sachdeva, Garima Sachdeva et al, Effect of Adjuvant Homeopathy with Usual Care in Management of thrombocytopenia Due to dengue Homoeopathy, *Homeopathy and Public Health*, 2019; 108: 151.
19. Staci Nix Williams Basic Nutrition and diet Therapy. First South Asia 14thed, 2,3.
20. Samuel Hahnemann, Organon of Medicine, 6th Reprint ed, 1996; 92.
21. Dr Asok Kumar Das Supplementary To A Treatise on Organon of Medicine (pt1) Reprint ed March, 2018; 156.