

## COMPARISON OF CATGUT VS SILK SUTURE MATERIAL FOR CLOSURE OF POST AURAL SKIN INCISION

Dr. Pankaj Srivastava<sup>\*1</sup>, Dr. Bhumika Trivedi<sup>2</sup> and Dr. Rohit Mehrotra<sup>3</sup>

<sup>1</sup>Director, Pankaj E.N.T Hospital, 56-C Singar Nagar, Alambagh, Lucknow-226005.

<sup>2</sup>ENT Consultant, Pankaj ENT Hospital, 56-C Singar Nagar, Alambagh, Lucknow-226005.

<sup>3</sup>MBBS, MS, Professor, GVSM Medical College, Kanpur.

Received on: 30/04/2022

Revised on: 20/05/2022

Accepted on: 10/06/2022

\*Corresponding Author

Dr. Pankaj Srivastava

Director, Pankaj E.N.T  
Hospital, 56-C Singar Nagar,  
Alambagh, Lucknow-226005.

### ABSTRACT

**Introduction:** The aim of the study is to compare Catgut with Silk in post aural skin incision closure and its healing. Forty patients undergoing Mastoidectomy or Tympanoplasty were taken in this study and divided in half for skin closure with either Catgut or Silk. Catgut closure of skin is cost effective as subcutaneous layer is already being closed with Catgut and same suture is used for skin closure. There is usually no need of stitch removal as it dissolves about in a week. Six patients suffered wound dehiscence whose skin had been closed with Catgut, Suture was immediately removed and they all healed by secondary intention. None had infection but this was due to proteolysis of suture material. Which led to proteolysis of surrounding skin. No other complication of wound healing was noted in the trial. No patient with Silk closure had any healing problem. **Conclusion:** Closure of post aural incision with Catgut is easy and cost effective but can sometimes create wound dehiscence due to proteolysis. Silk closure of has no disadvantage except added cost and need to remove it.

**KEYWORDS:** Catgut, silk, suture, tympanomastoidectomy, wound infection, dehiscence.

### INTRODUCTION

A variety of suture materials are available which may be classified upon their origin (organic and synthetic) or according to their durability in host tissues (absorbable and nonabsorbable). The essential features of suture material include knot safety, stretch capacity, tissue reactivity, and wound safety. Besides the adopted surgical and suturing technique, the choice of suture material may also influence the healing of the incised soft tissues.<sup>[1]</sup>

Catgut is natural collagen derived from sheep or cattle intestines and was first used circa 1876. The plain variety is absorbed in 10 days and a great tissue inflammatory response occurs. Chromic catgut is treated with a chromium salt to retard absorption; however, this causes an even greater tissue inflammatory reaction and the material is absorbed over 20 days. The degree of inflammation can interfere with wound healing due to the foreign body reaction, localized abscess formation and increased local tissue fluid associated with the inflammatory response. Catgut has low tensile strength and inconsistent surgical performance.<sup>[2]</sup>

Theodor Kocher began using silk sutures in the late nineteenth century as a result of the overwhelming number of surgical infections related to catgut. When compared to catgut, silk is not only cheaper but is also

more easily sterilized. Silk sutures tend to react less with tissues and result in stronger closures.<sup>[3]</sup>

Silk is an untangled mass of fibres woven by silkworms called as queen of textiles with beautiful lustre and unique properties. Silks are a group of fibrous proteins with high mechanical strength, antibacterial properties, biocompatibility, versatility in processing, the ease of sterilization, thermal stability and controllable degradation features making silk as promising biomaterial for many clinical functions. Silk suture facilitate easy passage through tissues and exhibit a good knotting strength and secure knot placement.<sup>[4]</sup>

Although new suture materials are being introduced into routine clinical otorhinolaryngological practice, objective comparison of the relative merits of the different suture materials is difficult because of the many variable factors, such as the age, sex, general condition of the patient and type of operation being performed, which could conceivably influence the outcome in an individual case. They found PDS and Prolene better is closure of post aural wound than Catgut and Silk.<sup>[5]</sup>

### MATERIAL AND METHOD

Patients admitted in Pankaj E.N.T Hospital undergoing ear surgery with postaural incision, from 1<sup>st</sup> August 2021 to 31<sup>st</sup> January 2022 were taken in this study.

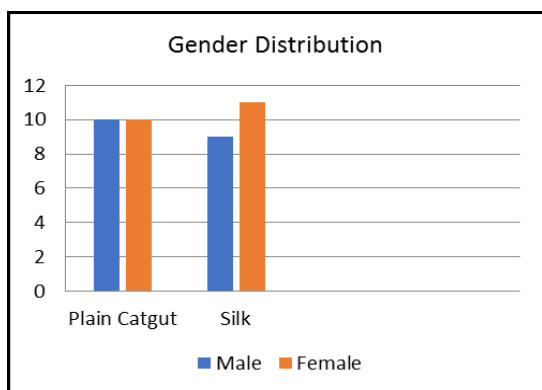
Patients were divided and randomized equally into two groups by age, gender and ear disease whether it was safe CSOM, Attic disease or any pathology needing post aural incision. Prior to each operation complete blood count, bleeding profile, Kidney function test, Liver function tests were done. At review the wound was examined to see if there was good healing, dehiscence, discharge of pus or extrusion of sutures. Wound infection was defined as the discharge of pus from the surgical incision site. Wound dehiscence was defined as gross separation of the wound edges with exposure of deep tissues. Proteolysis was defined as wound dehiscence with skin lysis at site of Catgut entry points with thinning of skin. In first group post aural skin was closed with 3-0 Plain Catgut with cutting needle with usual interrupted sutures and in the second group skin was sutured with 3-0 Silk on cutting needle.

When wound dehiscence with Proteolysis was noted, all Catgut sutures were immediately removed to stop proteolysis of Suture as well as skin and daily dressing done to allow secondary healing. All post Operative care and treatments were kept almost same in both the groups. Mastoid bandage was opened on seventh day and post aural Suture line was examined and noted. Patients were called every seventh day for examination upto one month.

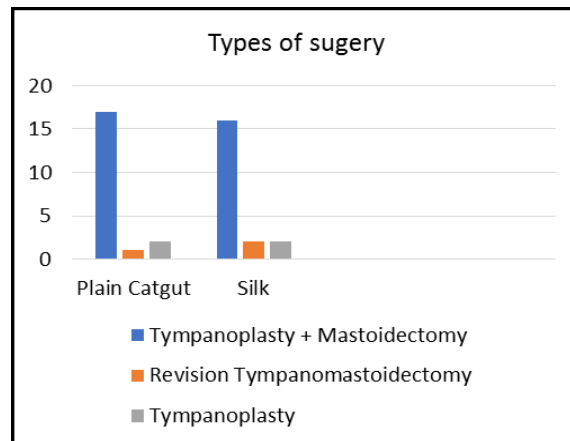
**OBSERVATIONS**

**Table 1: Patients number, age, gender, disease type and operation done.**

	Plain Catgut	Silk
No. of patients	20	20
<b>Gender</b>		
Men	10	9
Women	10	11
<b>Disease</b>		
Tubotympanic	16	16
Attic Disease	3	2
Revision Surgery	1	2
<b>Type of surgery</b>		
Tympanoplasty+Mastoidectomy	17	16
Revision Tympanomastoidectomy	1	2
Tympanoplasty	2	2



**Bar Chart 1: Gender wise distribution.**



**Bar Chart 2: Distribution according to type of surgery performed.**

In first group (plain catgut), 15 patients underwent tympanomastoidectomy, 3 patients underwent revision surgery and 2 patients underwent tympanoplasty. In second group (silk), 16 patients underwent tympanomastoidectomy, 2 patients underwent revision surgery and 2 patients underwent tympanoplasty.

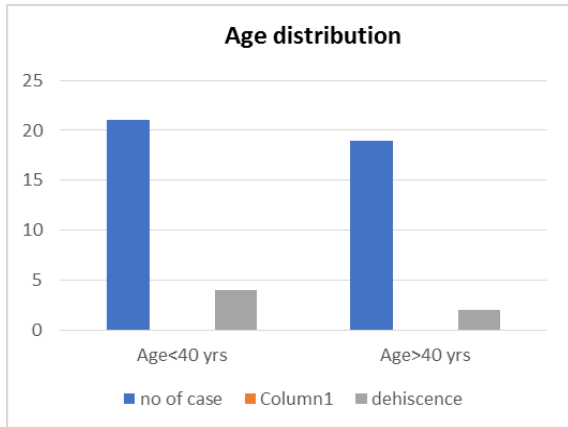
All patients received same antibiotic prophylaxis with cephalosporin (cefuroxime 500mg BD dose for 7 days. Tube drain was kept in all patients of each group.

It can be seen that the groups were well matched with regard to the age and gender of the patients, the type of surgery performed and the degree of bacterial contamination of the operative field. No patient had malignant disease, cytotoxic or steroid medication or significant haematological or biochemical abnormalities.

Moderate hypotension was induced intraoperatively in all cases. The length of the operation and therefore the period of hypotension did vary, but this was identical for all operations of a particular type and therefore matched for the two suture regimens.

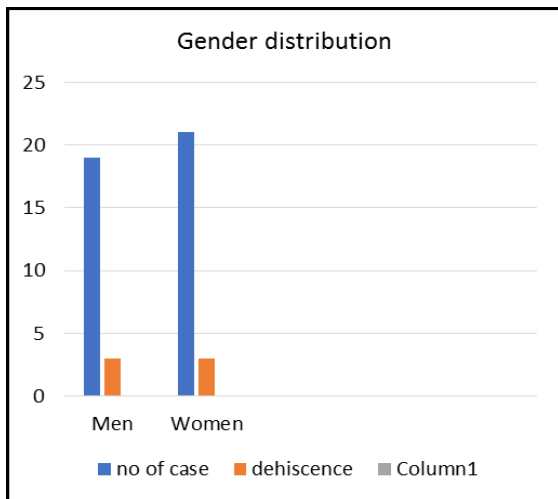
**Table 2: Incidence of wound dehiscence in relation to clinical variables.**

	No. of cases	Wound dehiscence
<b>Age</b>		
Less than 40 year	21	4
More than 40 year	19	2
<b>Gender</b>		
Men	19	3
Women	21	3
<b>Suture used</b>		
Plain Catgut	20	6
Silk	20	0
<b>Types of surgery</b>		
Tympanoplasty + Mastoidectomy	33	2
Revision Tympanomastoidectomy	3	3
Tympanoplasty	4	1



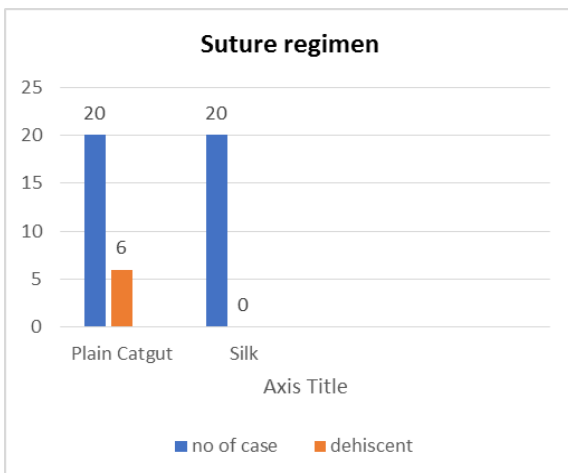
**Graph 1: Age wise distribution.**

Among 21 patients aged <40 years, 4 patients had wound dehiscence. Rest of 19 patients aged >40 years, among them 2 patients had wound dehiscence. This difference was not significant.



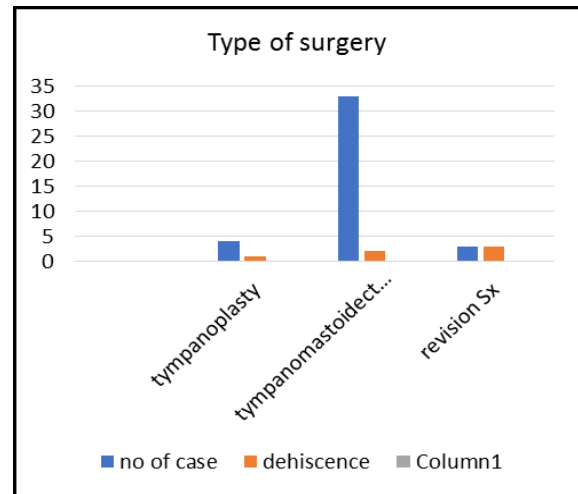
**Graph 2: Gender wise distribution.**

6 patients had wound dehiscence among them male and female patients were equal. This difference was not significant.



**Graph 3: Distribution according to type of suture used for skin closure.**

6 patients had wound dehiscence; all were closed by plain catgut.

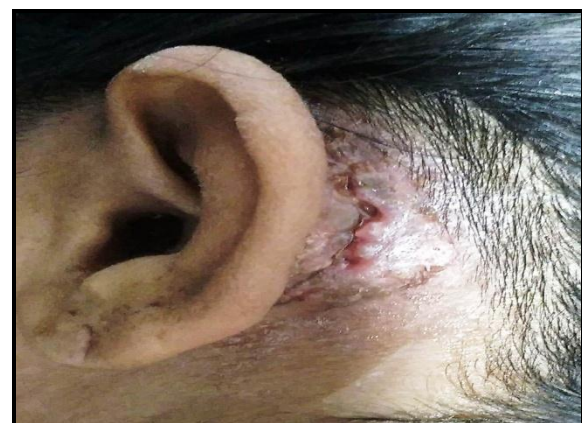

**Graph 4: Distribution according to types of surgery performed.**

6 patients had wound dehiscence, among which 2 patients under went tympanomastoidectomy, 3 patients underwent revision surgery and 1 patient underwent tympanoplasty.

**Table 3: Outcome in 6 cases of wound dehiscence.**

Suture	No. of wound infection	Time of wound infection (days after operation)	Outcome (days after operation)
Plain Catgut	6	7 minutes	All wound healed by 14 to 21 days



**7<sup>th</sup> post-op day wound dehiscence and proteolytic skin reaction noted. (skin closure done with catgut).**

Wound dehiscence occurred in the wounds of six patients. These wounds had been closed with plain catgut 3-0. Dehiscence noted on 7th post operative day. The incidence of wound dehiscence in relation to the type of suture and other clinical variables is shown in Table II. Wound dehiscence was significantly more common after closure with plain catgut. Revision surgery and status of the patients were not associated with a higher dehiscence

rate. The outcome in the patients who suffered wound dehiscence is shown in Table III. Wound dehiscence was managed with dressings, and the addition of appropriate antibiotic treatment. No patient suffered discomfort because of buried sutures. No patient suffered extrusion of sutures.

## DISCUSSION

The only complication noted was wound dehiscence with skin thinning (Proteolysis) in patients whose skin had been closed with catgut. There was no purulent discharge in any patient.

This superiority is due to a number of factors. Chromic catgut produces a polymorphonuclear reaction, and is absorbed by a proteolytic enzyme released from the lysosomes within the polymorphonuclear cell. The rate of loss of tensile strength of chromic catgut is such that very little strength remains after ten days, and it is quite unreliable as a suture in wounds requiring prolonged mechanical support. By contrast silk elicits only a mild tissue reaction and maintains its strength much longer.<sup>[5]</sup>

Although catgut and silk both are protein but catgut shows early reaction occasionally.

## CONCLUSION

This study has shown that post aural Skin incision closure with Plain catgut and Silk have their own positives and negatives, but if careful post operative watch is there Plain Catgut is cost effective and patient friendly.

## REFERENCES

1. Javed F, Al-Askar M, Almas K, Romanos GE, Al-Hezaimi KJISRN. Tissue reactions to various suture materials used in oral surgical interventions, 2012; 2012.
2. J La Bagnara Jr JJE, A review of absorbable suture materials in head & neck surgery and introduction of monocryl: a new absorbable suture. *Ear Nose Throat Journal*, 1995; 74(6): 409-15.
3. Tubbs RS, Verma K, Riech S, Mortazavi M, Oakes WJ, Cohen-Gadol AAJCSNS. Reaction to silk suture in children undergoing neurosurgery: case reports and review of the literature, *Childs Nerve Syst*, 2011; 27(3): 497-9.
4. Vishaka G V et al, Studies on Silk as a Suture in medical science. *The Pharma Innovation Journal*, 2019; 8(12): 97-100.
5. Willatt D, Durham L, Ramadan M, Bark-Jones, A prospective randomized trial of suture material in aural wound closure. *Journal Laryngology Otology*, 1988; 102(9): 788-90.