

WORKING WIDTH IN ENDODONTICS: A REVIEW

Dr. Basawaraj Biradar*¹, Dr. Sudharani Biradar², Dr. Aparna Palekar³, Dr. Mukund Singh⁴, Dr. Nikhil Borse⁵,
Dr. Neeraj Kumar⁶

¹Professor, Dept. of Conservative Dentistry, Rural Dental College, Loni, Pravara Institute of Medical Sciences, Maharashtra.

²Asst. Professor, Rural Dental College, Loni, Pravara Institute of Medical Sciences, Maharashtra.

³Professor & Head, Dept. of Conservative Dentistry, Rural Dental College, Loni, Pravara Institute of Medical Sciences, Maharashtra.

^{4,5}Reader, Rural Dental College, Loni, Pravara Institute of Medical Sciences, Maharashtra.

⁶Professor, Dept. of Conservative Dentistry, Sarswati Dental College, Lucknow.

Received on: 14/06/2022

Revised on: 04/07/2022

Accepted on: 24/07/2022

*Corresponding Author

Dr. Basawaraj Biradar

Professor, Dept. of
Conservative Dentistry, Rural
Dental College, Loni, Pravara
Institute of Medical Sciences,
Maharashtra.

ABSTRACT

Comprehensive understanding the anatomy of the tooth is responsible for the success of endodontic treatment. Working width is aims to address the horizontal dimension of a root canal diameter of the canal at the apex. Working width is one of the neglected part during endodontic therapy. Many in-vitro studies have recorded the scales and stated that very few clinical attempts to determine the working width. As the root canals are not always round in shape which were misinterpreted on two dimensional radiographs. Making the current working width during endodontic treatment is important. This article reviews the importance of working width and its considerations during endodontic treatment.

KEYWORDS: Working width, Root canal anatomy, Apical gauging, Apical tuning.

INTRODUCTION

The success of root canal treatment depends tooth along with proper biomechanical preparation, through disinfection and three dimensional obturation (coronal, lateral and apical) with fluid tight seal. Apical sealing of root canal is more important as its difficult to seal and poor visibility. For a proper apical sealing it requires complete debridement of apical area without removing unnecessary root dentin. Incorrect working width(WW) will cause either excess dentin removal or incomplete cleaning of the apical area.

Radiographs will never give the exact shape of the root canal as they are two dimensional view of three dimensional object. The correct working width can be determined by knowledge of internal anatomy of teeth and clinical experience by using suitable hand instrument.^[1] An incorrect gauging of the apical root canal diameter will lead to incomplete cleaning and shaping of the apical third of the root canal or can lead to extrusion of the debris and obturating materials into periapical area leading to failure of endodontic treatment.

CROSS SECTION OF THE ROOT AT APEX

Considering the cross section of apical part of the root different shapes of root canal were found.^[2] Depending on the minimal and maximum internal diameters (or

internal working width(IWW)) of the root canals (Figure 1) can be classified as:

- i. Round: Max IWW equals Min IWW
- ii. Oval: Max IWW is greater than Min IWW (Up to two times more)
- iii. Long oval: Max IWW is two or more times greater than Min IWW (up to 4 times more)
- iv. Flattened: Max IWW is four or more times greater than Min IWW.
- v. Irregular: Cannot be defined by i-iv

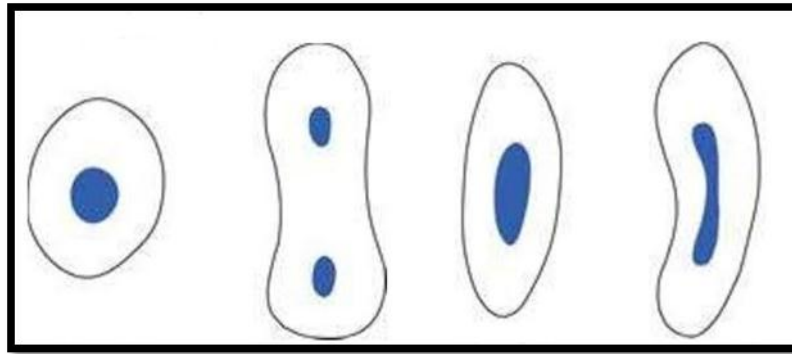


Figure 1: Different Types of apical root canal cross sections with comparison minimal and maximum internal diameters (or internal working width(IWW))

CURRENT CONCEPT OF WORKING WIDTH

The term ‘Working Width’ in endodontics was first introduced by Dr. Yi-Tai Jou et al. in 2004 at the University of Pennsylvania, to describe the diameter of the canal that corresponded to the tip size of the final instrument which reaches up to the working length.^[1]

The term ‘Apical Gauging’ is the measurement of the apical diameter or shape of a canal after initial crown-down shaping. (Glossary of Endodontic Terms by the American Association of Endodontists). ‘Apical Tuning’ is the clinical activity of recapitulating through a series of successively larger instruments and working them until they are observed to uniformly back out of the canal.

cross-sections of apical root canals will give better idea of Working width for understanding and studying. The correct working width (WW) is measured by an instrument which is slightly larger than that diameter of the apical root canal. So that this larger size instrument removes the most infected dentin and pulpal remnants from the apical part of root canal.

Earlier protocol suggested apical enlargement to be done three sizes greater than the first binding file at the apex or until white dentinal shavings appear on the instrument. But these techniques unable to eliminate all the microbes and debris from the root canal.^[3] Furthermore, the main drawback was no evidence that the first binding instrument will exactly reflects the diameter of the apical root canal and it remains unclear as to where this binding occurs along the entire length of the root canal^[4,5] as the apical root canals are not rounded all the times.

Recent developments in instrument design, cross-section, size and taper have improved the accuracy of apical gauging. root canal morphology, canal calcific metamorphosis, the pre-flaring of canal orifice and the instrument utilized for canal orifice pre-flaring have significantly affected apical gauging.^[6]

Cone beam computed tomography (CBCT) appears to be the most promising preoperative investigation for measuring working width compared to radiographs, Micro CT, Light speed rotary instrument technique and 2% taper hand instruments.^[7]

FACTORS AFFECTING DETERMINATION OF WORKING LENGTH

Factors affecting determination of working length and their features are described in table 1

Table 1: Factors affecting determination of working length.

Sr. No.	Factors	Features
1	Canal shape	The round canal can be measured easily than oval or flat canal
2	Canal length	Longer canal leads to greater frictional resistance which may affect a clinician's tactile sense to determine WW correctly.
3	Canal taper	Any taper discrepancy between the root canal and gauging instrument may lead to an early instrument binding of canal wall, causing a false sensation of apical binding
4	Canal curvature	Curved canals can cause deflection of gauging instrument & increased frictional resistance hence false reading
5	Canal content	Mixed canal contents (fibrous /calcified / aqueous) can lead to varying degrees of frictional resistance against the instrument used for gauging.
6	Canal wall irregularities	Convexities caused by attached pulp stones, denticles & reparative dentin or concavities on the canal wall lead to false estimation of true canal dimension.

CLEANING OF THE APICAL THIRD

Apical third cleaning is more difficult than other parts of root canal, because of its varying anatomy and limited instruments and instrumentation techniques for cleaning and shaping. The circumferential filing method, where the file is inserted to the working length and sequentially worked along all directions of root canal walls.

Later The light speed instrument technique, and non-instrumentation technology (NIT) were used for better cleaning and shaping of apical root canal. But they also did not clean completely at the apical part of the canal.^[8,9] Recently, Self Adjusting File(SAF) systems which claim to adapt to the canal shape introduced by RedentNova, which produce 3-dimensional cleaning of the apical part of the root canal.^[10] study done by Ana Arias et al (2017), SAF proved maintaining better original ribbon-shaped anatomy of the root canal compared to other rotary systems.^[10]

CONCLUSION

The concept of working width is recognized and followed by many endodontic faculties from long time. Even though after increased awareness, improved imaging technology, cleaning and shaping methods we are still in need of reliable device and technique to accurately determine the working width and its correct measurement. Further studies, technological advancements, and clinical guidelines required to adequate determination and management of working width.

REFERENCES

1. Jou YT, Karabucak B, Levin J, Liu D. Endodontic working width: current concepts and techniques. *Dent Clin North Am*, 2004; 48: 323-335.
2. Kenneth Hargreaves, Louis Bermann, Cohen's Pathways of the Pulp. 1st South Asian Edition. Elsevier Publishers.
3. Lussi A, Imwinkelried S, Hotz P, Grosrey J. Long-term obturation quality using instrumentation technology. *J Endod*, 2000; 26: 491-3.
4. Paque F, Zehnder M, Marending M. Apical fit of initial K files in maxillary molars assessed by micro-computed tomography. *Int Endod J*, 2010; 43: 328-35.
5. Wu MK, Barkis D, Roris A, Wesselink PR. Does the first file to bind correspond to the diameter of the canal in the apical region? *Int Endod J*, 2002; 35: 264-267.
6. Pecora JD, Capelli A, Guerisoli DM, Spano JC, Estrela C. Influence of cervical preflaring on apical file size determination. *Int Endod J*, 2005; 38: 430-435.
7. Marending M, Schicht OO, Paque F. Initial apical fit of Kfiles versus LightSpeed LSX instruments assessed by microcomputed tomography. *Int Endod J*, 2012; 45: 169-76.
8. Lussi A, Suter B, Fritzsche A, Gyax, Portmann P. *in vivo* performance of the new non-instrumentation technology (NIT) for root canal obturation. *Int Endod J*, 2002; 35: 352-8.
9. Lussi A, Suter B, Grosrey J. Obturation of root canals *in vivo* with a new vacuum technique. *J Endod*, 2003; 629-31.
10. Metzger Z, Teperovich E, Zary R, Cohen R, Hof R. The self-adjusting file (SAF). Part 1: respecting the root canal anatomy- -a new concept of endodontic files and its implementation. *J Endod*, 2010; 36: 679-690.
11. A. Arias et al. Effect of canal preparation with TRUShape and Vortex rotary instruments on three-dimensional geometry of oval root canals. *Aust Endod J*, 2017; 44: 32-9.