

MOYAMOYA DISEASE – A RARE CASE REPORT

***Dr. Azzan Mujahid, Dr. Yusra Arslan Khatri, Dr. Saman Anwar, Dr. Bisma, Dr. Rabia Ahmed and Dr. Misbah Tahir**

<p>Received on: 12/04/2023 Revised on: 02/05/2023 Accepted on: 22/05/2023</p> <p>*Corresponding Author Dr. Azzan Mujahid</p>	<p>ABSTRACT</p> <p>Moyamoya is a japnese word means puff of smoke. In this disease there is bilateral stenosis of supraclinoid parts of ICA with collateral formation which on conventional angiography gives appearance of puff of smoke.it is caused by gradual blockage of circle of willis and it may present as intracranial bleed or Ischemic infarctions. The gold standard for the diagnosis of Moyamoya disease is Cerebral angiography. The Authors identify a case of 17 years old male who presented with intraventricular hemmorage on CT head anf afterwards diagnosed with Moyamoya disease on cerebral angiography.</p>
--	--

INTRODUCTION

Moyamoya disease is a rare but progressive cerebrovascular disorder marked by chronic gradual blockage of the terminal portion of internal carotid arteries and or the proximal portion of the anterior cerebral arteries and middle cerebral arteries leading to formation of collateral vessels.^[1,2,4] this gradual stenosis affects important part of the cerebral vasculature, leads to the development of collateral vasculature (moyamoya vessels) at the base of brain.^[1,2] cerebral angiography I the gold standard investigation for diagnosis and grading of this disease, of which “a puff of smoke” (moyamoya vessels) signals seen via catheter angiography at the base of brain is the most important diagnostic criteria.^[5]

CASE REPORT

A 17years old young male presented in ER with complain of fever headache altered level of consciousness for 2 days with no known comorbid. At the time of admission in our hospital his GCS was E2M5V1, Chest and abdomen was unremarkable. His vitals show blood pressure 140/65mmhg, Heart rate 68 beats/minute, temp 100 F, RR 22/min. All baseline investigations were done which were unremarkable except ESR - 25(raised). Due to low GCS he was intubated and got his CT scan head done which showed right occipital hematoma with intraventricular hemorrhage.

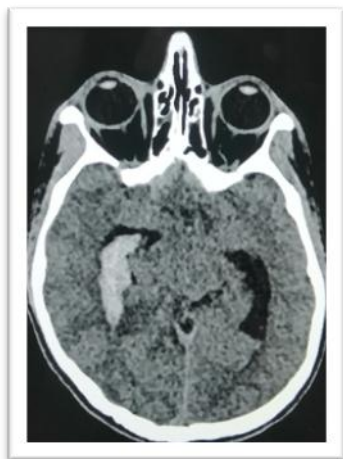
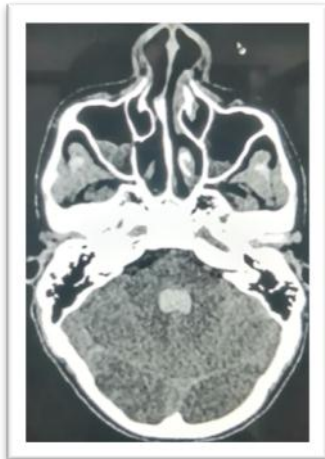
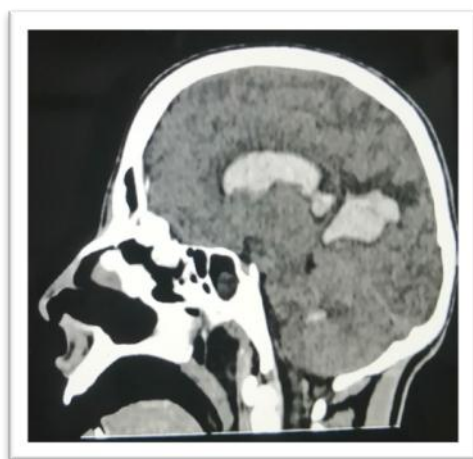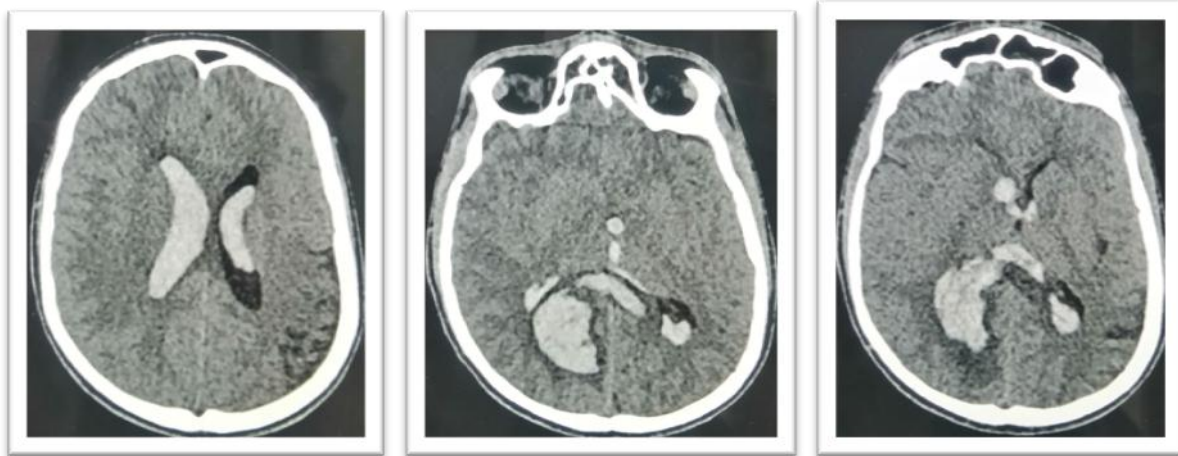
FIGURE 1.1



1.2



1.3



1.4

1.5

1.6

Figure 1.1 -1.6 CT scan head showing hematoma in right occipital region with mild perifocal edema, blood is also seen in both lateral, 3rd and 4th ventricle representing interventricular hemorrhage.

Cerebral angiogram done which showing occlusion of supraclenoid segments of both ICA A1 and M1 segments of MCA and ACA, network of small vessels seen in

adjacent to it giving puff of smoke appearance. Findings overall suggestive of Moyamoya disease.

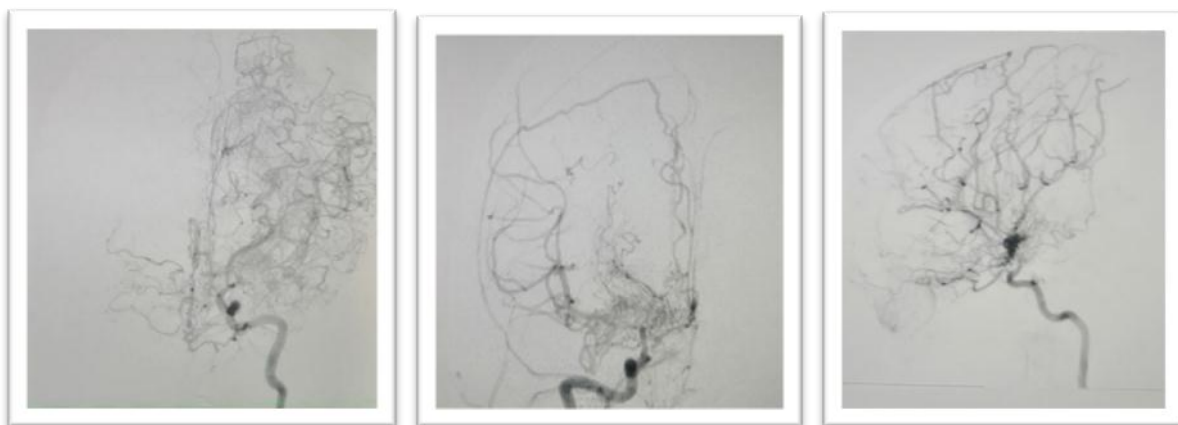
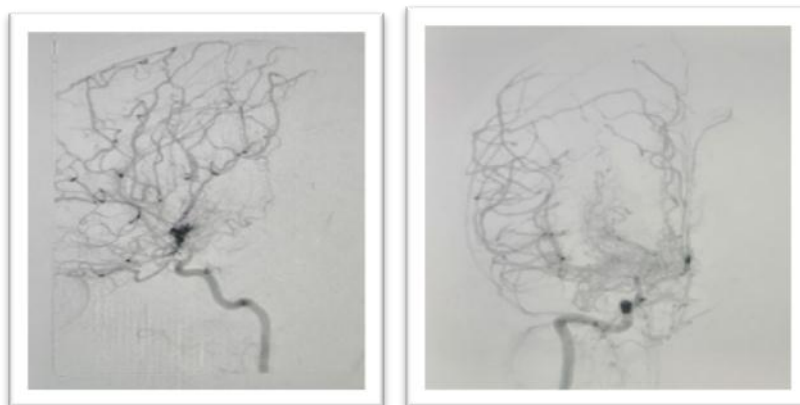


Figure 2.1

2.2

2.3



2.4

2.5

Cerebral angiogram (frontal lateral and oblique views) showing stenosis of supraclenoid parts of bilateral internal carotid arteries the A1 and M1 segments of both ACA and MCA are occluded. Collaterals formation in lenticulostriate regions giving puff of smoke appearance. A small aneurysm is also appreciated arising from these arteries.

He was managed on conservative and supportive treatment with antibiotic, anti-epileptics antipyretic, after

12 days of admission is discharged to home with GCS of 14 by 15.

DISCUSSION

Moyamoya word is use in Japanese. Moyamoya disease has also been termed “bilateral hypoplasia of the ICAs,” “cerebral juxta-basal telangiectasia,” “cerebral arterial rete,” “rete mirabile,” “cerebral basal rete mirabile,” and, more commonly, “spontaneous occlusion of the circle of Willis.”^[1,2,3] The prevalence of MMD is higher in East Asian countries compared to other regions, ranging from 10.5/100,000 in Japan to 16.1/100,000 in South Korea. The incidence has a bimodal distribution pattern with two peaks, one at the age of years old, and the other one later in life, at the ages of 35-50 years old. Generally, the incidence in females is slightly higher than in male.^[1,2,4] Moyamoya disease has been under recognized or recognized or present with either ischemic or haemorrhagic event.^[1,2,3,5] The clinical presentation of MMD includes transient ischemic attacks (TIA), ischemic stroke, hemorrhagic stroke, epilepsy, headache and cognitive dysfunction.^[1,2] Most pediatric patients present with ischemic symptoms including TIA -s and ischemic strokes.^[1] There is no definitive treatment for MMD. Prognosis of MMD depends on the severity of the symptoms, the precise location and the extent of the occlusion, as it dictates the clinical presentation and guides the therapeutic effort. Conservative management includes the use of aspirin as prophylaxis for further strokes or thrombotic events, in addition to anticonvulsant and analgesic medications to manage the seizures and headache.^[1] Surgical treatments are divided into 3 types: direct, indirect, and combined/other methods. Direct bypass includes superficial temporal artery-MCA bypass or use of other graft types. Indirect procedures bring in circulation to the intracranial regions by introducing newly developed vasculature from newly approximated tissues. These procedures may not be enough to prevent further ischemia; therefore, a combination of direct and indirect procedures is more suitable. Direct and indirect revascularization surgeries are performed to improve blood circulation in the affected region.^[2,4,5]

CONCLUSION

Moyamoya disease is a rare cause of stroke either ischemic or hemmorrhagic. Hemmorrhagic stroke is caused by rupture of collaterals formed in this disease. Catheter angiography is gold standard for the diagnosis. Revascularization surgeries can be done for the treatment.

REFERENCES

1. Musa J, Rahman M, Guy A, Guy A, Saliyaj K, Siddik AB, Hyseni F, Elezi K, Kola I, Cobo A, Ahmetgjekaj I. Silent Moyamoya disease-A rare case report. *Radiology Case Reports*, 2021 Jun 1; 16(6): 1368-73.

2. Burke GM, Burke AM, Sherma AK, Hurley MC, Batjer HH, Bendok BR. Moyamoya disease: a summary. *Neurosurgical focus*, 2009 Apr 1; 26(4): E11.

3. Funaki T, Takahashi JC, Houkin K, Kuroda S, Takeuchi S, Fujimura M, Tomata Y, Miyamoto S. Angiographic features of hemorrhagic moyamoya disease with high recurrence risk: a supplementary analysis of the Japan Adult Moyamoya Trial. *Journal of neurosurgery*, 2017 Apr 14; 128(3): 777-84.
4. Gupta A, Tyagi A, Romo M, Amoroso KC, Sonia FN. Moyamoya disease: a review of current literature. *Cureus*, 2020 Aug 30; 12(8).
5. Okuyama T, Kawabori M, Ito M, Sugiyama T, Kazumata K, Fujimura M. Outcomes of Combined Revascularization Surgery for Moyamoya Disease without Preoperative Cerebral Angiography. *World neurosurgery*, 2022 Sep 1; 165: e446-51.