

LIVER HISTOPATHOLOGICAL STUDY OF SILK DYE EFFLUENT INDUCED SWISS ALBINO MICE *MUS MUSCULUS* AND ITS MITIGATION BY USING *MORINGA OLEIFERA* LEAF POWDER

Dr. Serina Khatun*

University Dept. of Zoology, T.M.Bhagalpur University, Bhagalpur-812007, India.

Received on: 31/07/2023

Revised on: 21/08/2023

Accepted on: 11/09/2023

*Corresponding Author

Dr. Serina Khatun

University Dept. of Zoology,
T.M.Bhagalpur University,
Bhagalpur-812007, India.

ABSTRACT

The silk dye effluent is one of the most potential harmful chemicals liberated in the environment in an unexpected manner. Silk dye waste is widely used as a potent dyeing of yarn and fabrics in many countries and has been shown to produce some adverse health effects. This work focuses primarily on the effects of *Moringa oleifera* leaf extract on liver surface ultra structure of silk dye effluent induced toxicity in Swiss albino mice *Mus musculus*. The liver tissue has been taken an account for surface histopathological study. The mice were divided into 5 Groups i.e. Group I (Control), Group II (fed with 50% silk dye), Group III (fed with 100% silk dye), Group IV (mice fed with 50% dye treated with *M. oleifera* leaves powder), Group V (mice fed with 100% dye treated with *M. oleifera* leaves powder) have been taken for experiment. The dose of silk dye was 2ml/day to both groups II and III and *M. oleifera* leaf is given as per the standard dose (300mg/kg b.w) to both animals of group IV and V. Administration of silk dye waste result were demonstrated atrophy of liver, enlargement of the sinusoidal space, vacuole formations in hepatocytes, infiltrations with haemorrhage in hepatic tissue but used of *Moringa oleifera* leaf powder it was significantly recovered the damage tissues has been observed. This study suggested that the extract may have beneficial effect on histopathological constituents such as Liver.

KEYWORDS: Silk dye effluent, *Moringa oleifera* leaf powder, Histopathology of Liver, Swiss albino male mice, toxicity assessment.

INTRODUCTION

Liver is a vital organ which present in vertebrate, has a wide range of functions including detoxification and protein synthesis. The liver is our greatest chemical factory, it builds complex to simple substances absorbed from the digestive tract, it neutralises toxins, it produces bile which aids fat digestion and removes toxins through the insides (Maton *et al.*, 1993). The ability of the liver functions is often compromised by numerous substances which exposed to on a daily basis, these substances include certain medical agents which taken in over doses and sometime when introduced within therapeutic ranges injures the organ (Gagliano *et al.*, 2007).

Silk dye effluent is one of the major sources of hazardous pollutants. Industrialization is a boon of independent India but that is allied with hazardous effluents and discharges polluting the environment. Silk industry provides an important economic stand to the artisans but the dye waste or spent wash arising from the manufacturing unit cause great menace if released in the open. Silk dye waste effluents are more toxic to environment than the domestic sewage. Bhagalpur (25°17' N latitude and 86°83' E longitude) is endowed

with age old silk fabric and yarn production units. Here, the manufacturers use mostly synthetic dye such as azo dyes as colorant for their products. Azo dye forms the largest and most important silk industry provides an important economic group of synthetic dyes (Mathur *et al.*, 2005). Meyer in 1981 reported that the chemical structure of azo benzene and azo naphthol derivatives.

Moringa oleifera or drumstick tree is a tropical plant widely known to be of possible great medicinal values (Fahey, 2005; Paliwal *et al.*, 2011). It is a plant native to India, Pakistan, Bangladesh and Afghanistan and grows up to 5 or 10 meters in height. *Moringa oleifera* is considered to be an important medicinal plant. It is being used as anti-ulcer, diuretic, anti-inflammatory and wound healing agent (Caceres *et al.*, 1991; Udupa *et al.*, 1994; Bassey *et al.*, 2013). Its leaves are used as nutritional supplement and growth promoter because of significant presence of protein, selenium, calcium, phosphorus, β -carotene and γ -tocopherol in it (Nambiar and Seshadri, 2001; Lakshminarayana *et al.*, 2005; Sanchez-Machado *et al.*, 2006). The therapeutic use of *Moringa* leaves have been extensively studied in treatment of anti-toxicity and antioxidant (Khatun, 2017; Khatun and Varma, 2017).

But no work has been done on its property to mitigate the damages induced by silk dye waste on histopathological observation on testis and sperm profile of a mammal. Hence the present work has been undertaken to study the impact of silk dye waste on different profiles of albino mice and their subsequent recovery by application of *Moringa oleifera* leaf powder.

This study was therefore designed to investigate the effect of *Moringa oleifera* on silk dye waste induced histopathology of liver in albino male mice.

MATERIALS AND METHOD

Experimental animals: Experiment was performed on 6 to 8 weeks old healthy laboratory inbred male *Mus musculus* weighing about 30 to 35 grams. The animals were obtained from University Department of Zoology, Bhagalpur. Mice were reared and maintained at the animal house of University Department of Zoology, T.M.Bhagalpur University, and Bhagalpur under standard conditions and fed with nutritional diet and water.

Collection of plant material: *Moringa oleifera* leaf powder has been procured from own home product (with the help of ECHO Technical Note, By Beth Doerr and Lindsay Cameron, 2005, North Fort Myer, FL 33917, USA) Bhagalpur, Bihar, India.

Collection of silk dye waste: Silk dye waste effluents were collected directly from discharge point of silk dye industries of Nathnagar, Bhagalpur at regular interval.

Experimental design: The mice were divided into 5 groups. Gr-I (control mice), Gr-II (mice treated with 50% silk dye waste), Gr-III (mice treated with 100% silk dye waste), Gr-IV (mice fed with 50% dye treated with *M. oleifera* leaves powder), Gr-V (mice fed with 100% dye treated with *M. oleifera* leaves powder).

Dosage: The control group was given normal food and water. Silk dye waste was administered orally 2ml/day (Chaurasia *et al.*, 2005) group II and III for 30 and 60 days duration. *M. oleifera* leaf powder was also fed orally 300mg/kg b.w to both the group IV and V for 30 and 60 days exposure as per the method suggested by Chatterjee *et al.*, 2013.

Biological assays: Histopathological study of liver tissues on silk dye waste induced male mice *Mus musculus* and their mitigation by using medicinal or herbal plant as *Moringa oleifera* leaf powder.

Tissue processing and staining: After 30 and 60 days of experiment, mice were sacrificed and their organ were removed, were fixed in fixative and paraffinised, Haematoxylin-Eosin stained sections of liver were observed under light microscope (Pears, 1985) on 10X magnification.

RESULTS

Histopathology of Liver: Examination of HE section of the liver in control group (Gr-I) mice showed normal histoarchitecture as well as normal architecture of CV, HC and HS (Plate:1). Upon treatment with 50% and 100% silk dye waste (Gr-II and III) after 30 days showed the liver section appeared many change such as PHC, DHS, DCV, DIV, RIV, OS and DBHA when compared with Group-I animals tissue section (Plate: 2.i & 3.k). In case of Gr- II and III treated with 50% and 100% silk dye effluent induced animal for 60 days incubation period the liver section appeared variable changes such as DSH, DLIV, DCV, DHC, BHC, OS and DLI when compared with Gr-I animal (Plate: 4.m & 5.o). In case of Gr-IV and V when treated with *Moringa oleifera* leaf powder for 30 days showed the improvement in liver section, show the normal architecture of HS, RIV, RHS, RS and HC when compared with Gr-II and III (Plate: 2.j & 3.l). Upon treatment with *M. oleifera* leaf powder for 60 days incubation period in Gr- IV and V mice showed regenerated HS, CV, IV, IBD, RBV, RIV and LIV when compared with animals of Gr-II and III (Plate: 4.n & 5.p).

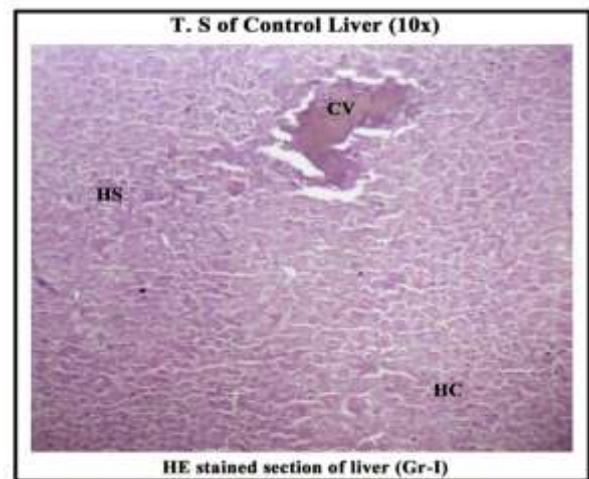
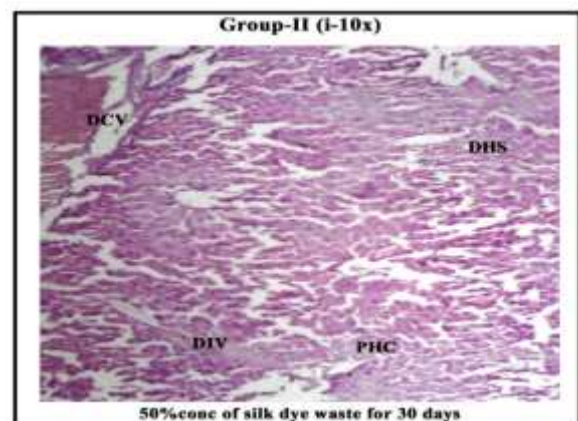


Plate: 1.

Captions: CV- Central vein, HC- Hepatic Cells and HS- Hepatic Sinusoids



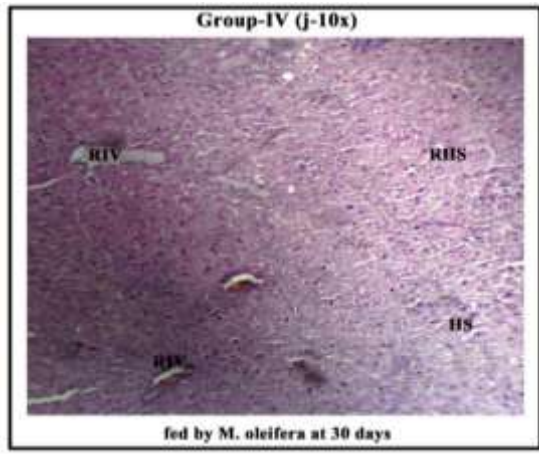


Plate: 2.

Captions: HS- Hepatic Sinusoids, DCV- Disrupted Central Vein, PHC- Pore in Hepatic Cells, DHS- Disrupted Hepatic Sinusoids, DIV- Disrupted Interlobular Vein, RHS- Regeneration Hepatic Sinusoid and RIV- Regeneration Interlobular Vein

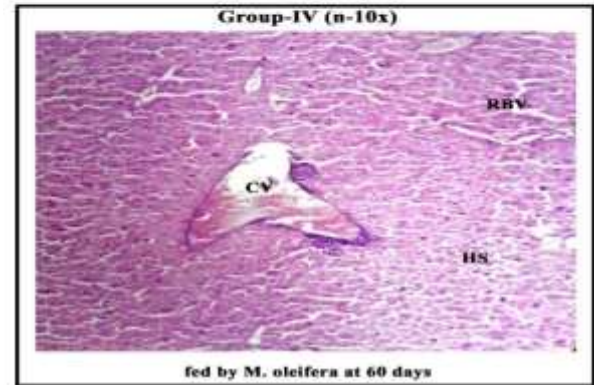
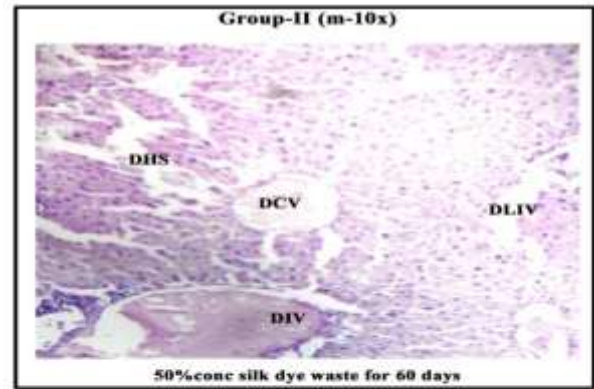


Plate: 4.

Captions: HS- Hepatic Sinusoids, DHS- Disrupted Hepatic Sinusoid, IV- Interlobular Vein, RBV- Regular Blood Vessels DCV- Damaged Central Vein, DLIV - Disrupted Large Interlobular Vein and IBD- Interlobular Bile Duct.

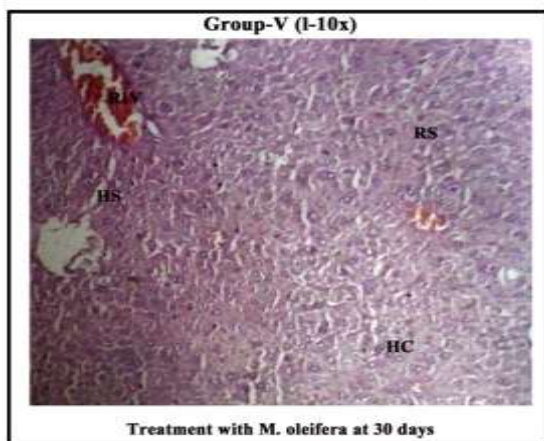
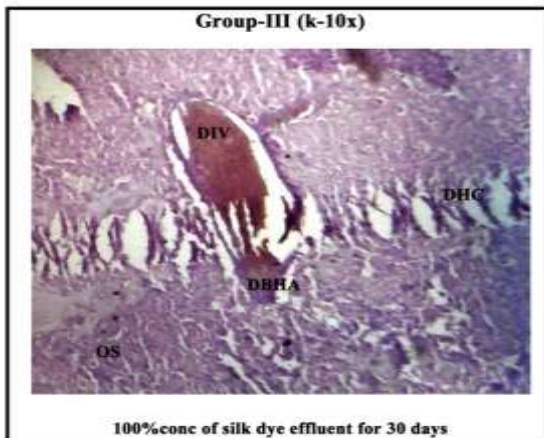


Plate 3.

Captions: HS- Hepatic Sinusoids, DHC- Disrupted Hepatic Cells, DIV- Disrupted Interlobular Vein, RIV-Regeneration Interlobular Vein, OS- Obliterated Sinusoid, HC- Hepatic Cells, RS- Regular Sinusoid and DBHA- Disrupted Branch of Hepatic Artery

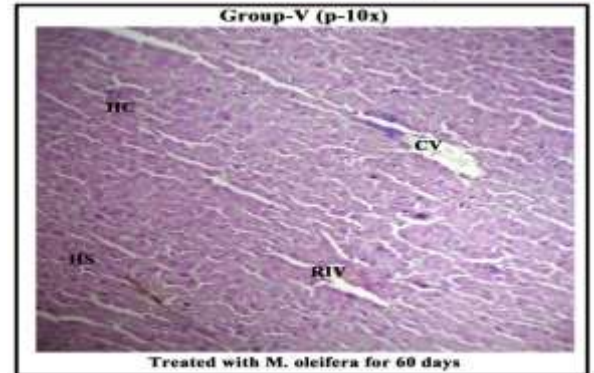
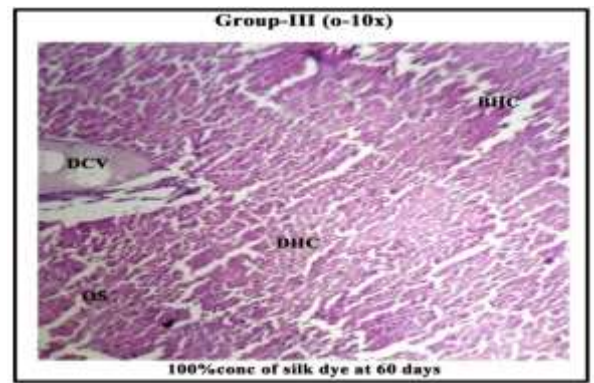


Plate: 5.

Captions: **HS-** Hepatic Sinusoids, **LIV-** Large Interlobular Vein, **DCV-** Disrupted Central Vein, **DLI-** Disrupted Large Interlobular Cell, **CV-** Central Vein, **OS-** Obliterated Sinusoid, **DHC-** Disrupted Hepatic Cell, **RIV-** Regenerated Interlobular Vein and **BHC-** Breakage Hepatic Cell

DISCUSSION

The results show that the *M. oleifera* leaf extract when fed to Group IV and V mice, showed the significant recovery of liver when compared with mice of Gr- II and III.

In the present study, the histopathological change in the liver of silk dye waste treated mice suggest additional specific pathological pathway may be involved in silk dye hepatotoxicity and liver cell injury may be attributed to iron deposition in hepatocytes (El-Zayadi, 2006). The liver is well known target organ of the toxic impact regarding its function in biotransformation and excretion of xenobiotic (Roganovic and Jordanova, 1998). Selmanoglu and Akay (2000) who reported similar Histopathological changes including mononuclear cell infiltration, congestion and hepatocellular damage in the liver of male rats treated with dimethoate, endosulfan and carboxyl. (Sayim, 2007; Gokcimen *et al*, 2007; Elhalwagy *et al*, 2008 and Muthuviveganandave *et al*, 2011) suggested that may occur haemorrhage, inflammatory cell infiltration. The results from the present experiment are in agreement with the finding studied by Grewal *et al*, (2010). Additional specific pathogenic pathway may be involved in nicotine hepatotoxicity, as reported by El-Zayadi (2006), Yildiz (2004) and Muthukumaran *et al*. (2008), liver cell injury, inflammation and activation of Kupffer cells may be attributed to pro-inflammatory cytokines (El-Zayadi, 2006). These similar results are reported for Malathion and other pesticides indicating exposure of these pesticides leading to encourage histological disturbances in experimental animals (Ahmad *et al*, 2009; Yousef *et al*, 2003; Adeniran *et al*, 2006).

On the other hand, *M. oleifera* attenuates histological damage by increasing the level of GSH (Yumei *et al.*, 2006; Heileh and Theresa, 2008). Histopathological study of the toxicity effect of silk dye waste on Kidney of Swiss albino mice *Mus musculus* and mitigation by using *Moringa oleifera* leaf powder (Khatun, 2017). Serina Khatun in 2017 also reported that the toxicity of silk dye waste on lung of Swiss albino male mice *Mus musculus* and its mitigation by using *Moringa oleifera* leaf extract. Exposure to toxicity caused significant decrease in hepatic superoxide dismutase level (Muthukumaran *et al*, 2008;). The mitigation effect of green tee on nicotine toxicity may be attributed to anti-inflammatory and antioxidant properties (Varilek *et al*, 2001; Patra *et al*, 2008; Zhen *et al*, 2007;.) and the free radicals scavenging properties (Neogy *et al*, 2008) through decreased lipid peroxidation and suppressed oxidative damage; both caused oxidative damage in lead treatment animals

(Ogura *et al*, 2008). Moreover, Gardner *et al*. (1925) have the effects of carbon tetrachloride depended on the mode of administration, a point also made by the post-administration of Wistar rats with leaf extract of *Moringa oleifera* remarkably modulated the oxidative stress caused by alcohol administration. The reversal of elevated serum intracellular enzyme levels by *M. oleifera* extract after ethanol administration may be attributed to the stabilizing ability of the cell membrane preventing enzymes leakages as earlier postulated by Pari *et al.*, in 2007. *Moringa oleifera* leaf extract on silk dye waste induced histopathotoxicity on liver and testis of Swiss albino male mice *Mus musculus* reported by Khatun and Varma (2017).

CONCLUSION

This study concludes that silk dye induced any alteration of histopathological change in liver can be mitigated by using of *Moringa oleifera*. On the basis of above discussed diagram and facts it can be concluded that the *M. oleifera* leaf powder significantly reduce the alteration arisen in hepatotoxicity and associated histological structures in the toxicity impact of silk dyes waste induced male mice.

REFERENCES

1. Adeniran, O.Y; Fafunso, M.A; Adeyemi, O; Lawal, A.O; Ologundudu, A and Omonkhua, A.A: Biochemical effects of pesticides in serum and urinoogical system of rats. *J Applied Sci*, 2006; 6: 668-672.
2. Ahmed, M. and Nasr, H.M. Dimethoate-induced changes in biochemical parameters of experimental rat serum and its neutralization by black seed oil. Slovak, *J. Anim. Sci.*, 2009; 42: 87-94.
3. Basse, R.B; Bala, D.N; Edagha, I.A and Peter, A.I: The effect of ethanolic extract of *Moringa oleifera* on alcohol-induced testicular histopathologies in pre-pubertal albino Wistar rats. *Biology and Medicine*, 2013; 5: 40-45.
4. Caceres, A; Cabrera, O; Morales, O; Mollinedo, P. and Mendia, P. Pharmacological properties of *M. oleifera*. 1: preliminary screening for antimicrobial activity. *Journal of Ethnopharmacology*, 1991; 33(3): 213-216.
5. Chatterjee, P.K; Vinodini, N.A; Anwar, A; Nayanatara, A.K' Pal, S.R and Suman, V.B The front end in anti-electrostatic discharge for production, innovation, development: Polycarbonate/grapheme Composite. *Int. J. of Inv in Sci. Eng. And Tech*, 2013; 2(9): 4724-4734.
6. Chaurasia, O.P; Kumar, A. and Kumari, M. Genotoxic effect of silk dyeing waste in bone marrow cells of mice. *Mus musculus*, *Cytologia*, 2005; 70(4): 381-384.
7. Elhalwagy, M.E.A; Darwish, N.S. and Zaher, E.M. Prophylactic effect of green tea polyphenols against liver and kidney injury induced by fenitrothion insecticide. *Pestic. Biochem. Phys*, 2008; 91: 81-89.

8. El-Zayadi, A.R: Heavy smoking and liver. *World. J. Gastroenterol*, 2006; 12(38): 6098-6101.
9. Fahey, J. W. (2005). *Moringa oleifera*: A review of the medical evidence for its nutritional, therapeutic, and prophylactic properties. Part 1. *Trees for Life Journal*.
10. Gardner, G.H; Grove, R.C; Gustafson, R.K; Maire, E.D; Thompson, M.J; Wells, H.S. and Lamson, P.D. Studies on the pathological histology of experimental carbon tetrachloride poisoning. *Bull. Johns. Hopkins. Hosp.*, 1925; 36: 107-133.
11. Gagliano, N.; Grizzi, F and Annoni, G: Mechanism of aging and liver functions. *Digest. Dis. Sci.*, 2007; 25: 118-123.
12. Grewal, K.K; Sandhu, G.S; Ranjit Kaur; Brar, R.S and Sandhu, H.S: Toxic impact of Cypermethrin on Behavior and Histology of certain tissues of albino rats. *Toxicol Int*, 2010; 20: 61-67.
13. Gokcimen, A; Gulle, K; Demirin, H; Bayram, D; Kocak, A and Altuntas, I: Effect of diazinon at different doses on rat liver and pancreas tissues. *Pesticide Biochem. Physiol*, 2007; 87: 103-108.
14. Heileh, S; Therasa, S.C (2008): *M. oleifera* polyphenols down regulates cyclooxygenase and Bcl-2 activity in acetaminophen induced hepatotoxicity. *Springer Sciences Media, LLC*.
15. Khatun S. (2017, April). Histopathological study of the toxicity effect of silk dye waste on Kidney of Swiss albino mice *Mus musculus* and mitigation by using *Moringa oleifera* leaf powder., *Advance Research Journal of Multidisciplinary Discoveries*, 2017; 12.0,C-1: 01-04
16. Khatun. S and Varma. M.C: Role of *Moringa oleifera* leaf extract on silk dye waste effluent induced histopathotoxicity on liver and testis of Swiss albino male mice *Mus musculus*. *IOSR Journal of Pharmacy*, 2017; 7: 4(1): 1-4.
17. Lakshminarayana, R; Raju, M; Krishnakantha, T.P and Baskaran, V. Determination of major carotenoids in a few Indian leafy vegetables by high-performance liquid chromatography. *Journal of Agricultural and Food Chemistry*, 2005; 53(8): 2838-2842.
18. Mathur, N; Mehta, M; Chaudhry, V: Sperm abnormality Induction by Food colour metanil yellow. *J. Ecolphysiol. Occup. Hlth*, 2005; 5: 157-160.
19. Maton, A; Jean, H; McLaughlin, C.W; Warner, M.Q; Lattart, D and Wright, J.D (1993): Human Biology and Health. Eaglewood Cliffs, New Jersey, Prentice Hall, USA.
20. Muthuviveganandave, V; Muthuraman, P; Hawang, I. and Srikumar, K. Biochemical and Histopathological changes induced by low doses of carbendazin on testis of male albino rat. *International Journal of Pharmacy and Biological Sciences*, 2011; 1(4): 572-576.
21. Muthukumaran, S, Sdheer, A.R; Menon, V.P. and Nalini, N: Protective effect of quercetin on silk dye induced pro-oxidant and antioxidant imbalance and DNA, 2008; 13(5): 217-224.
22. Neogy, S; Mahapatra, S; Mandal, S.K. and Somenath, R: Amelioratory effect of *Andrographis paniculata* Neem on liver, kidney, heart, lung and spleen during nicotine induced oxidative stress. *Environ. Toxicol. Pharma*, 2008; 25: 321-328.
23. Nambiar, V.S and Seshadri, S: Bioavailability trials of β -carotene from fresh and dehydrated drumstick leaves(*M. oleifera*) in a rat model. *Plant Food for Human Nutrition*, 2001; 56(1): 83-95.
24. Ogura, R; Ikeda, N; Yuki, K; Morita, O; Saigo, K; Blackstock, C; Nishiyama, N. and Kasamatsu, T: Genotoxicity studies on *M. Oleifera* leaves powder. *Food Chem. Toxicol*, 2008; 46: 2190-2200.
25. Paliwal, R.; Sharma, V.; Pracheta; Sharma, S.; Yadav, S. & Sharma, S. Anti-nephrotoxic effect of administration of *Moringa oleifera* Lam in amelioration of DMBA-induced renal carcinogenesis in Swiss Albino mice. *Biol. Med.*, 2011; 3(2): 27-35.
26. Roganovic, Z.D. and Jordanova, M. Liver lesions in bleak collected from some contaminated sites on lake Ohrid. A Histopathological evidence. *Ekol. Zast. Zivot. Sred.*, 1998; 6: 11-18.
27. Sanchez-Machado DL, Lopez-Cervantes J, Vazquez NJ, High-performance liquid chromatography method to measure α and γ -tocopherol in leaves flowers and fresh beans from *M. oleifera*. *Journal of Chromatography A.*, 2006; 1105(1-2): 111-114.
28. Sayim, F: Dimethoate- induced biochemical and histopathology change in the liver of rats. *Exp. Toxicol. Pathol*, 2007; 59: 237-243.
29. Serina, K. Toxicity of silk dye waste on lung of Swiss albino male mice *Mus musculus* and its mitigation by using *Moringa oleifera* leaf extract. *Inter. J. of Current. Adv. Res.*, March, 2017; 6(3): 2657-2660.
30. Selmanoglu, G. and Akay, M.T. Histopathological effects of the pesticide combinations on liver, kidney and testis of male albino rats. *Pesticides*, 2000; 15: 253-262.
31. Varilek, G.W; Yang, F; Lee, E.Y; DeVilliers, W.J; Zhong, J; Oz, H.S; Westberry, K.F. and McClain, C.J: *Moringa oleifera* polyphenol extract attenuates inflammation in interleukin-2-deficient mice, a model of autoimmunity. *J. Nutr.*, 2001; 131(7): 20-34.
32. Yildiz, D. Nicotine, its metabolism and an overview of its biological effects. *Toxicol*, 2004; 43: 619-632.
33. Yousef, M.I; Demerdash, F.M; Kamel, K.I. and Al-Salhen, K.S. Changes in some haematological and biochemical indices of rabbits induced by isoflavones and cypermethrin, *Toxicology*, 2003; 189: 223-224.
34. Yumei, F; Zhou, Y; Zheng, S. and Chen, A. The antifibrogenic effect of epigallocatechin gallate results from the induction of de novo synthesis of glutathione in passaged rat hepatic stellate cells. *Lab. Invest*, 2006; 86: 697-709.

35. Zhen, M; Wang, O; Huang, X; Cao, L; Chen, X; Sun, K; Liu, Y; Li, W. and Zhang, L: Green tea polyphenol epigallocatechin-3-gallate inhibits oxidative damage and preventive effects on carbon tetrachloride induced hepatic fibrosis. *J. Nutr. Bioch*, 2007; 18: 795-805.
36. Udupa, S.L; Udupa. A.L and Kulkarni, D.R. Study on the anti-inflammatory and healing properties of *M. oleifera* and marmelos. *Fitoterapia*, 1994; 65(2): 119-123.