

CHRONIC GRANULOMATOUS INVASIVE FUNGAL RHINOSINUSITIS – A CASE REPORT

Dr. Binay Debbarma*

Asst. Prof., Dept. of Otorhinolaryngology. AGMC, Agartala, Tripura.

Article Received on: 20/10/2023

Article Revised on: 10/11/2023

Article Accepted on: 30/11/2023



*Corresponding Author

Dr. Binay Debbarma

Asst. Prof., Dept. of

Otorhinolaryngology. AGMC,

Agartala, Tripura.

INTRODUCTION

Allergic fungal rhinosinusitis is an increasingly recognized type of hypertrophic sinus disease (HSD) disorders that clinically and immunologically appears analogous to allergic bronchopulmonary aspergillosis. The presence of fungal hyphae within the sinus is important in the etiology of fungal rhinosinusitis.^[1]

Based on histopathology finding, five basic diagnostic categories of fungal rhinosinusitis disorders are currently recognized. The lesions can be broadly divided into two categories the invasive and non-invasive. The two non-invasive fungal rhinosinusitis disorders are; fungal ball (sinus mycetoma) and allergic fungal sinusitis (AFS) and the other three types of fungal rhinosinusitis are tissue-invasive infectious disease; acute necrotizing (fulminant) fungal rhinosinusitis, chronic invasive fungal rhinosinusitis and granulomatous invasive (indolent) fungal rhinosinusitis.^[2]

The fulminant type of fungal infection occurred in immunocompromised persons. The indolent forms and noninvasive forms occurred in immunocompetent persons.^[6]

Chronic granulomatous (indolent) invasive fungal rhinosinusitis may present as a chronic hypertrophic sinus disease in an immunocompetent patient.^[1] Mucosa-invasive fungi are usually encapsulated within the surrounding granulomas. Widespread tissue necrosis, angioinvasion, or polymorphonuclear leucocytic infiltration is usually not seen.^[5] There may be two forms of the disorder. One form is more chronic and recurring fungal infection first reported from Sudan, also called primary paranasal granuloma, in which cultures for *Aspergillus flavus* are commonly positive.^[5,3]

The other form is limited to fungal microinvasion of the superficial mucosa and has been suggested to be the sinus equivalent of bronchocentric granulomatosis because it has occasionally been in concert with allergic fungal sinusitis.^[4]

The treatment of choice of acute fulminant fungal rhinosinusitis is proper surgical resection with antifungal drugs.^[1]

A patient was presented to ENT Dept., Regional Institute of Medical Sciences, Imphal with ulceration and scab formation following painful swelling at right medial canthal area with no history of diabetes, tuberculosis. The patient was earlier suspected to be a case of sinonasal malignancy and 2 (two) courses of chemotherapy (CHOP) was given elsewhere. The patient developed sign and symptoms of fulminant fungal infection with repeated positive fungal culture.

CASE REPORT

A 58 years old man was referred to RIMS hospital, Imphal, for ulceration and scab formation following painful swelling at right medial canthal area for 3(three) months (Fig.1). The patient was earlier suspected to be a case of sinonasal malignancy and 2 (two) courses of chemotherapy were given elsewhere thereafter he developed alopecia and ulceration in the medial canthus of right eye. At the time of admission patient had mild pain at the ulcerated right medial canthal area. The patient was afebrile and had alopecia.

On anterior rhinoscopy, the right lateral nasal wall was covered with a blackish membrane in the region of the middle meatus. Middle turbinate was absent because of the previous surgeries.

Endoscopic examination revealed loss of middle turbinate, anterior ethmoid cells and a thin darkish membrane separating the right nasal cavity from the right orbit, granulation tissue in and around the maxillary

ostium which was almost completely obstructed by the granulation tissue.

The left nasal cavity and sinuses were free of any obvious pathology. Sphenoid sinuses were also not involved on both sides. Antibiotic started in view of secondary infection, however patient developed severe right periorbital cellulitis and intolerable pain.

Routine hematological and biochemical investigations reports were Hb-12 gm%, TLC-5200/cumm with N-81%, L-18%, E-01%, ESR-95 mm/1st hr. The blood glucose fasting and PP were 78mg% and 112mg%. ELISA test for HIV antibody was negative. There was no history of tuberculosis. X-ray chest PA view was normal. CT scan of nose and PNS showed homogenous soft tissue mass in the right maxillary sinus, posterior ethmoid and frontal sinus (fig.2). HPE of nasal biopsy and ulcerated area showed presence of fungal element – septate hyphae (10% KOH wet mount). Repeated specimens of nasal swab, nasal biopsy and ulcerated area

for fungal culture in SDA (Sabouraud dextrose agar) media confirmed it to be *Aspergillus fumigatus* (Fig.3).

The patient was not responded to oral itraconazole; hence treatment was switched over to Amphotericin-B. A total dose of 575mgs of Amphotericin-B was infused with dose of 50mgs in 500ml of 5% dextrose solution on alternate day after the sensitization test dose. There was subsequent improvement with disappearance of cellulitis. The disease was cleared from the right maxillary sinus, right frontal sinus, and right posterior ethmoid endoscopically (FESS).

In due course the patient developed high grade fever with chest symptoms. Chest X-ray showed an opacity in the right mid-zone (? fungal). But patient subsequently developed renal impairment with pedal oedema hence the therapy was switch-over to Voriconazole. The patient could not afford the treatment because of high cost of drug and was discharged on request.

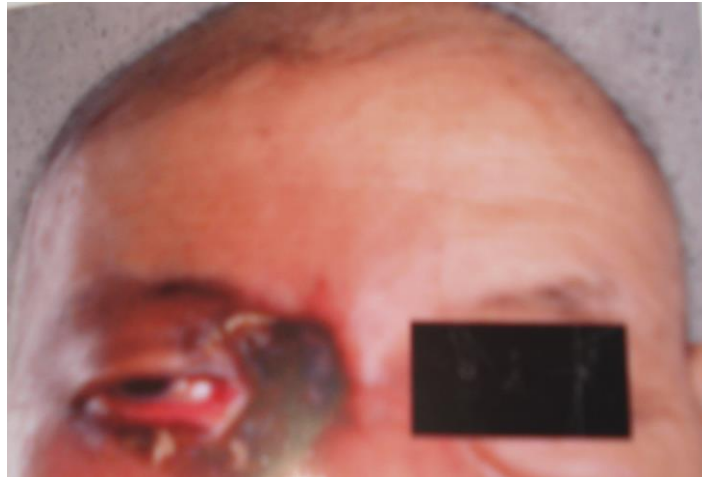


Fig. 1: Showing ulceration and scab formation at right medial canthus region in alopecic patient

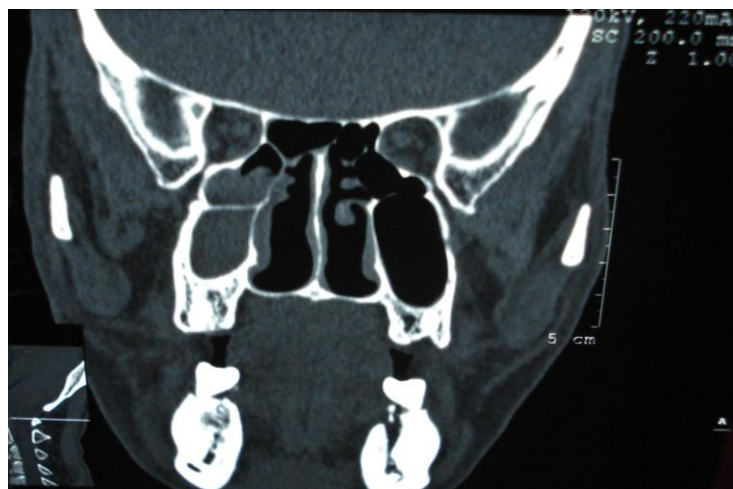


Fig. 2: CT scan PNS coronal view showing soft tissue mass shadow in right maxillary and ethmoidal sinus

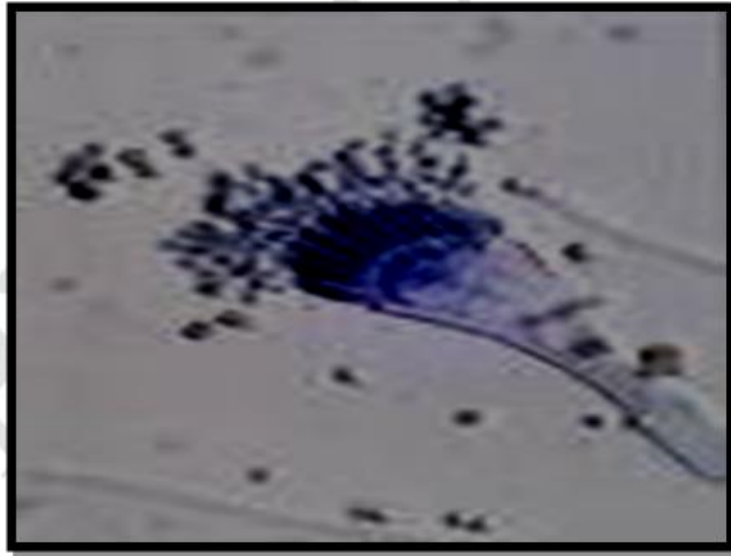


Fig. 3: Lactophenol Cotton Blue (LCB) preparation showing *Aspergillus fumigatus* (40X).

DISCUSSION

The patient presented with history of painful swelling and ulceration with scab formation in the right medial canthal and ethmoidal region following chemotherapy. In spite of repeated endoscopic excisional biopsy the disease was not diagnosed. But from the records available with the patient no investigations for fungal infection were available. Our clinical impression on first examination was fungal infection of nose and PNS and subsequently proved by the skin biopsy, fungal culture and histopathological examination.

The oral itraconazole was not responded hence injection Amphotericin-B was given with initial disappearance of signs and symptoms but due to the toxicity and further spread of infection to the right lungs, the therapy was switched over to Voriconazole. Although the disease was cleared from the right maxillary, ethmoidal and frontal sinuses endoscopically, the disease spread to the other system of body due to fulminant in nature.

We considered the case to be chronic granulomatous invasive fungal sinusitis because the patient was immunocompetent at beginning and he developed pain and swelling with fungal mass in the sinuses and which subsequently developed to fulminant fungal infection, following immunosuppression. Amphotericin-B is the drug of choice for invasive fungal sinusitis but if the patient can not tolerate its toxicity, Voriconazole is the alternative drug of choice. Long term follow up is recommended.

Demonstration of *Aspergillus* by both culture and microscopic examination provides the most firm diagnosis. The positive direct microscopic examination and repeated isolation on culture confirms the diagnosis beyond doubt. Fungal etiology may be considered whenever patients present with any sinonasal symptoms and cutaneous lesion in this area where fungal infection

prevalence is high. Such a high index of suspicion may reveal underlying systemic fungal infection. It will benefit the patient by instituting early diagnosis and treatment regime.

ACKNOWLEDGEMENT

The authors are thankful to the Director, RIMS, Imphal for allowing us to publish this case report. I also express our gratitude and love to the patient who have voluntarily agreed to take his photograph for the publication of this paper in the journal.

REFERENCES

1. Mark S. Schubert, Allergic fungal sinusitis. *Otolaryngol clin N Am*, 2004; 37: 301-324.
2. De Shazo RD, O' Brien M, Chapin K. et al: Criteria for the diagnosis of sinus mycetoma. *J Allergic clin Immunol*, 1997; 99: 4755 - 4785.
3. Milosev B, el-Mahgoub S, Aal OA, et al. Primary aspergilloma of Paranasal sinuses in the Sudan: a review of seventeen cases. *Br J Surg*, 1969; 56: 132-137.
4. Schubert MS and Goetz DW. Evaluation and treatment of allergic fungal sinusitis. L Demographics and diagnosis. *J Allergy Clin Immunol*, 1998; 102: 387-394.
5. Veress B. Malik OA. el-Tayeb AA. et al. Further observation on the primary Paranasal aspergillois granuloma in the Sudan: a morphological study of 46 cases. *AM J Trop Med Hyg*, 1973; 22: 765 -772.
6. Manning SC, Marie M, Kevin K, Frank V and Marple BF: Computed tomography and magnetic resonance diagnosis of allergic fungal sinusitis, *Laryngoscope*, 1997; 107: 170 -176.